SANAMED
2013; 8(2): 151–157
ISSN-1452-662X

UDK: 616.36-001.3
Pregledni rad

THE BLUNT LIVER TRAUMA — REVIEW OF CURRENT DIAGNOSTIC AND MANAGEMENT STRATEGIES

Doklestic Krstina,[1, 2] Karamarkovic Aleksandar[1, 2]

[1] School of Medicine, University of Belgrade, Serbia
[2] Clinic for Emergency Surgery, Clinical Center of Serbia, Belgrade, Serbia

Primljen/Received 10. 09. 2013. god. Prihvaćen/Accepted 15. 11. 2013. god.

Abstract: The liver is one of the most commonly injured organs in blunt abdominal trauma. Major liver trauma in polytraumatic patients accounts for significant morbidity and mortality. Therapeutic options for blunt hepatic trauma include both non-operative and operative management. Hemodynamic status, not the grade of the injury, should dictate the management. CT scan of the abdomen and pelvis is a standard diagnostic modality in hemodynamically stable trauma patients. Recent advancements in imaging studies and enhanced critical care strategies have shifted the paradigm for the management of liver injuries. Nonoperative management of both low- and high-grade injuries can be successful in hemodynamically stable patients. Direct suture of bleeding vessels, vascular isolation of the liver, and damage control surgery have improved outcomes in the hemodynamically unstable patients. We have reviewed current position in the treatment of blunt hepatic trauma.

Keywords: Liver injury, perihepatic packing, damage control surgery (DCS), angioembolization, haemodynamic instability, focused assessment by ultrasound for trauma (FAST), computed tomography (CT), intensive care unit (ICU).

INTRODUCTION

Despite the relative protection by the rib cage, the anterior position in the abdomen and fragile tissue make the liver the most commonly injured abdominal organ in blunt trauma (1–3). Liver trauma represent 1.2–4.6% of all cases hospitalised for trauma (3–6). The most frequently, liver injury is found in the second and third decades of life, and is more common in males, which can be explained by contemporary causes of trauma (1–6). Hepatic injuries are commonly associated with lesions of other abdominal organs that may demand emergency laparotomy, irrespective of the grade of liver injury (5).

Management of liver injury has evolved in the last decades. Massive hemorrhage from liver remains a major threat to the life of the patient and the greatest challenge for the surgeon. At the beginning of the twentieth century, Pringle showed that compressing the portal vessel inflow may control the bleeding and stopp the hemorrhage from deep liver wounds (7). In early 1970s, more than 80% of the liver injuries were managed operatively. Advancement of imaging studies plays a key role in the conservative approach. In late 1990s, 80–90% of these injuries were successfully managed by nonoperative means.

Though the mortality rate from blunt liver injury has significantly decreased over the last decades, treatment of complex liver trauma is still controversial and challenging for the clinicians (2). Multidisciplinary approach to the management of complex liver injuries shows better outcome, with less blood transfusion, early recovery time and less intensive care days (3). Use of Focused assessment by ultrasound for trauma (FAST), introduction of computed tomography (CT) scan, availability of angiography, enhanced critical care monitoring in an intensive care unit (ICU) and damage control surgery (DCS) have led to great progress in treatment of liver injuries (2–6).

This review discusses the contemporary diagnostic methods and therapeutic approach to blunt liver trauma.

MATERIAL AND METHODS

We searched the English language publications on MEDLINE, PubMed, EMBASE, ISI Web of Science: Science Citation Index Expanded (SCI-EXPANDED). The reference lists of review, eligible studies and the trials were undertaken to determine the current diagno-

stic and management strategies in blunt liver trauma. The current literature was reviewed using search words: blunt liver injury, perihepatic packing, damage control surgery, angioembolization. Information we collected included grading of liver trauma, diagnostic methods and treatment of liver injuries and outcome. In the following, we will present and discuss the results of research.

CLASSIFICATION OF LIVER INJURIES

A grading of liver trauma, based on severity of the injury, was introduced in 1989 by Moore and modified in 1995 (Table 1) (8, 9). The AAST (American Association for the Surgery of Trauma) established a detailed classification system that has been adopted as a reference in the world literature (9). Since 1981, the great majority of blunt liver injuries are diagnosed by CT. The most of Grade I and II injuries can be managed nonoperatively, if there is no other source of bleeding or hollow viscus injury in hemodynamically stable patients (2, 3). The Grade III, IV, and V injuries are complex, problematic and controversial in clinical practice (5, 9, 10).

DIAGNOSTIC METHODS

Evaluation of patients who have sustained blunt abdominal trauma present a significant diagnostic challenge to the most trauma surgeon. The initial management to trauma patient with potential hepatic lesion has been even more performed according to "Advanced Trauma Life Support" (ATLS) (11). The initial goal is to resuscitate the patient. Because of the recognized inadequacies of physical examination, trauma surgeons have come to rely on a number of diagnostic adjuncts and it was important to develop an evidence-based, systematic diagnostic approach to blunt abdominal trauma (12).

Diagnostic peritoneal lavage (DPL)

In 1965, Root et al. introduced diagnostic peritoneal lavage (DPL), and one of their recommendations was that it can be used in diagnosing intraperitoneal bleeding following blunt trauma (13). DPL is not enough specific and may result in nontherapeutic unnecessary laparotomies in up to 30% of patients (14). Nowadays, the FAST and CT scans have generally replaced the invasive DPL. However, the Advanced Trauma Life Support course still recognizes DPL as a diagnostic method in emergencies (5).

Ultrasonography

Focused assessment by ultrasound for trauma (FAST) is noninvasive method, useful for initial trauma evaluation (15–17). The purpose of FAST exam is to provide a quick assessment for hemoperitoneum and hemopericardium, by sonographic evaluation of pericardium, right upper quadrant, including Morrison's pouch, left upper quadrant and the pelvis. This evaluation is not designed to identify the degree of organ injuries. The sensitivity and specificity of this examination are 63–100% and 95–100%. (16, 17). Negative FAST

Table 1. *Liver injury scale (1994 revision)*

Grade	Type of Injury	Description of injury
I	Hematoma	Subcapsular, < 10% surface area
	Laceration	Capsular tear, < 1 cm parenchymal depth
II	Hematoma	Subcapsular, 10% to 50% surface area intraparenchymal < 10 cm in diameter
	Laceration	Capsular tear 1–3 parenchymal depth, < 10 cm in length
III	Hematoma	Subcapsular, > 50% surface area of ruptured subcapsular or parenchymal hematoma; intraparenchymal hematoma > 10 cm or expanding
	Laceration	> 3 cm parenchymal depth
IV	Laceration	Parenchymal disruption involving 25% to 75% hepatic lobe or 1–3 Couinaud's segments
V	Laceration	Parenchymal disruption involving > 75% of hepatic lobe or > 3 Couinaud's segments within a single lobe
	Vascular	Juxtahepatic venous injuries; ie, retrohepatic vena cava/central major hepatic veins
VI	Vascular	Hepatic avulsion

examination does not exclude intra-abdominal injuries or hemoperitonium. Retroperitoneal injuries and hollow viscus injuries can also be missed by ultrasound evaluation. Contrast-enhanced sonography improved the diagnostic accuracy in terms of identification of ongoing hemorrhage in the liver, size and completeness of the injury, as compared to non-contrast sonography (18).

AST, ALT

Transaminases (AST, ALT) are present in high concentrations in hepatocytes, and they released into the circulation following acute traumatic hepatocellular injury. Elevation of the serum liver enzymes AST and ALT have been reported as predictors of liver injury due to blunt abdominal trauma (19, 20). One previous observational cohort study has reported serum ALT to be a sensitive diagnostic marker when evaluating harm caused by blunt hepatic injuries (21). It would appear that patients with raised ALT > 2 times normal were 7.2 times more likely to possess major hepatic injury. This risk increased to 8.4 times with simultaneous raised AST and ALT > 2 times (20, 21).

Computed tomography (CT)

The year 1981 marked the introduction of computed tomography (CT) for diagnosing visceral injuries following blunt trauma (22). Today, CT scan is the standard imaging study for hemodynamically stable patients following blunt trauma (23, 24) (Figure 1).

CT scan is the first imaging study which gives relatively detailed delineation of solid organ injuries and retroperitoneal injuries as well. Severity of injuries is also graded based on CT scan examination (12, 25, 26). The sensitivity and specificity of the CT scan for liver injuries are 92–97% and 98.7%, respectively (12, 26). Extravasation of contrast demonstrated on CT scan (35–40 HU) indicates active bleeding from the injury site and further intervention is needed (26, 27). Another important advantage of CT in liver trauma menagment is the diagnosis of late complications (28, 29). For high-grade injuries (grades IV–V) follow-up CT scan is recommended after 7–10 days to determine the injury status and complications as well (30). CT scan-guided percutaneous drainage may also be performed when complications such as biloma and intra-abdominal collections occur. CT and improvements in intensive care (ICU) play an integral role in the nonoperative management of liver trauma in haemodynamically stable patients (3–5, 28).

MANAGEMENT

Nonoperative management

The finding that 50–80% of haemorrhages due to hepatic lesions stop spontaneously, is leading to 20–67% of non-therapeutic laparotomies (3–5, 28, 30). The success rate of conservative treatment has progressively increased to 89–98% (30, 31).

Angiography and angioembolization has become the gold standard in the management of blunt liver trauma for hemodynamically stable patients, if a contrast extravasation is seen on CT scan, unless they have associated injuries that require surgical treatment. It is not the grade of the injury, but rather the hemodynamic parameters of the patient which dictate the nonoperative management versus operative management decision. If the CT scan shows Grade I or II liver injury, with no associated injuries within the peritoneal cavity

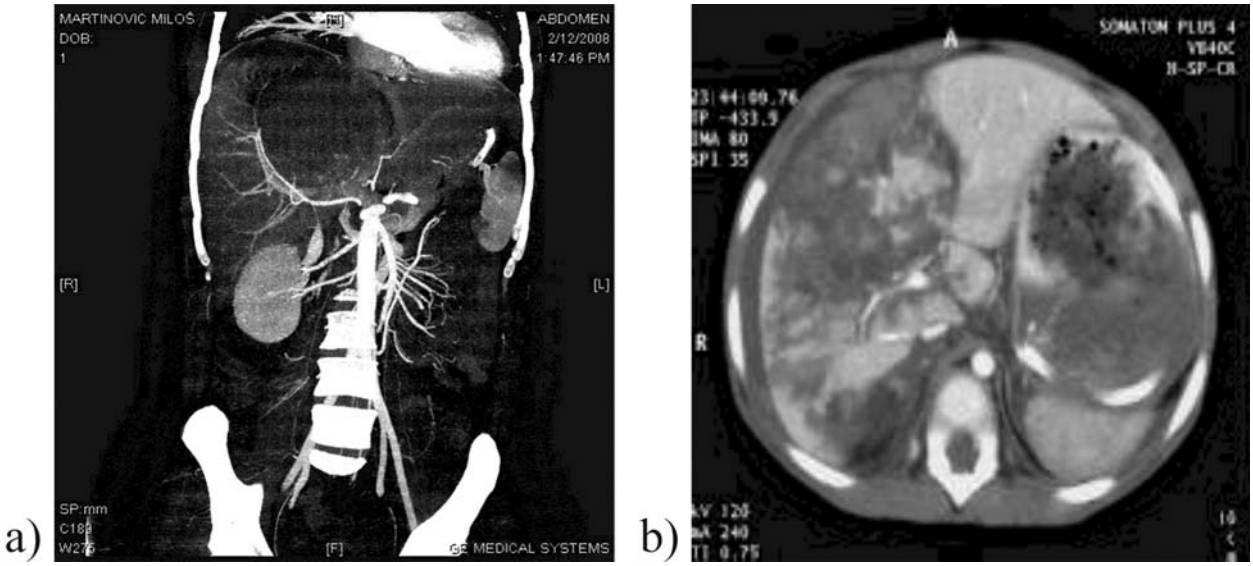

Figure 1. *Computed tomography(CT)- massive rupture of the liver (S4-S8)*

or retroperitoneum, and they are maintaining hemodynamic stability, the patient can be admitted to the department. If CT scan shows a Grade III, IV, or V injury and the patient is hemodynamically stable, and if there is minimal blood loss within the peritoneal cavity and no associated injuries, the patient should be monitored in the ICU. Post-operative angioembolization is also reported in damage control surgery prior to removal of packing, if rebleeding is suspected (32). The sensitivity and specificity of angiogram identifying active bleeding in liver injuries is 75% and the success rate of controlling the hemorrhage is 68–93% (32, 33). There is an overall survival benefit and 23% reduction of mortality for conservative approach in blunt liver injury (33, 34). All of these patients managed nonoperatively will require CT scans 4 to 7 days following injury. This will diagnosis bilomas and hepatic necrosis and may show arterial aneurysms or fistulas (34). The most common reasons for failure of the nonoperative management are delayed haemorrhage and active extravasation of contrast not controlled by angioembolization (34, 35).

Operative management

Hemodynamic instability remains the main indication of the operative approach in liver trauma (2, 30). Rebleeding, constant decline of hemoglobin and increased transfusion requirement, as well as the failure of angioembolization of actively bleeding vessels are a few factors which indicate the need for laparotomy (30, 36). If the patient has a Grade III, IV, or V liver injury and extensive intraperitoneal blood, exploratory laparotomy is indicated as soon as possible (4, 5). The control of hemorrhage is the primary objective and the unstable patient should not remain in the emergency room more than 15 minutes (30). The operative approach includes a wide range of temporary and definitive surgical procedures. Direct suture ligation of the parenchymal bleeding vessel, perihepatic packing, hepatorrhaphy, repair of venous injury under vascular isolation and DCS with preoperative and/or postoperative angioembolization are the preferred methods, compared to anatomical resection of the liver and use of the atriocaval shunt (5, 37).

If the patient develops the triad of coagulopathy, acidosis, and hypothermia, it is indication to perform DCS including temporarily perihepatic packing and to take the patient to the ICU for continued resuscitation, and warming to repair the three components of the triad (30, 38) (Figure 2).

The first and the most important step in DCS is to pack all four quadrants with pads and manually compress the liver using both hands for 15–20 minutes. If

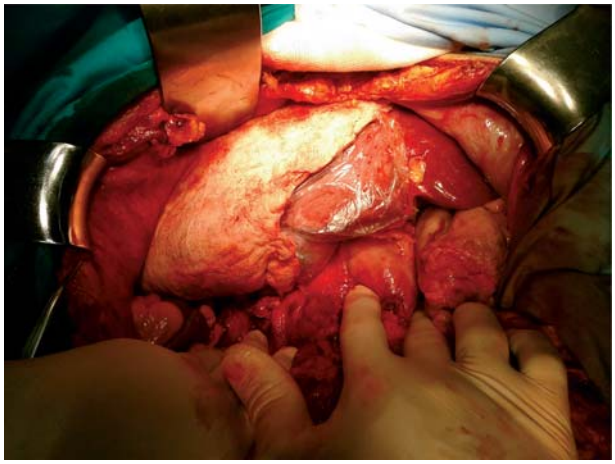

Figure 2. *Perihepatic packing*

the spleen is actively bleeding, splenectomy should be performed. The laceration of liver tissue is usualy limited to venous and parenchymal bleeding and compression for an extended period of 15 minutes, can occasionally achieve homeostasis. If bleeding continues, then perform the Pringle maneuver by clamping the v. porta hepatis with a soft clamp or Rummel tourniquet. If this controls the hemorrhage, that can allow the assess the liver laceration to identify the bleeding vessel and direct suture ligation should be performed using 3-0 or 4-0 absorbable suture. Finaly, hemostatic agents such as fibrin glue, surgicell, and gel foam soaked in thrombin can be used after repair of liver injuries (39).

As soon as the metabolic derangement is corrected, the patient should be taken back to operating room for re-exploration. Another consideration, after the triad of coagulopathy, hypothermia, and acidosis has been corrected, is arteriography/embolization before returning the patient to the operating room. Usually, 48 hours is the safe period for re-exploration and second look operation: reassessment of liver viability or missed abdominal injury, peritoneal toilet and closure of the abdominal incision (38). It may be necessary to do resectional debridement or liver resection.

Combined injuries of the inferior vena cava and liver befall into the most complex traumas (30). Patients who arrive in shock and fail to respond to initial resuscitative measures, those who are still actively bleeding at the time of laparotomy, have a low probability of survival. Injuries of the retrohepatic inferior vena cava and the liver, have mortality rate up to 71–78% and death most commonly is caused by intraoperative exsanguination (30). If bleeding continues despite the Pringle maneuver, the surgeon must consider more extensive procedures. This requires mobilizing the right lobe and occasionally the left lobe and vascular isolation of the liver. The preferred method for caval and hepatic vein injury is total vascular isolation (30, 40, 41). The

procedure consists of performing a Pringle maneuver, and clamping of the inferior vena cava above and below the injury. Superiorly, the inferior vena cava can be isolated placing a Statinsky clamp across the suprahepatic vena cava just below the diaphragm and inferiorly, just above the renal veins. This approach allows direct repair of the vascular injury and debridement or liver resection. If the patient develops coagulopathy, acidosis, or hypothermia, damage control surgery should be considered. Aortic clamping is not recommended for the vena caval or hepatic vein injury (30). The vascular isolation technique has reported a better survival rate compared to atriocaval shunt or veno-veno bypass (30).

Intraoperative autotransfusion "Cell Saver" (CS)

Intraoperative autotransfusion with washed salvaged blood is a useful method for treatment of massive bleeding (42). Commonly known as a "Cell Saver" (CS), the intraoperative cell salvage machine suctions, washes, and filters blood, so it can be given back to the patient intraoperativly. CS provides an effective and cost-efficient resuscitation strategy as an alternative to allogeneic blood transfusion in trauma patients undergoing emergency operative procedures (42).

Extracorporeal circulation in the severe liver and/or inferior vena cava injury

The concept of extracorporeal circulation in the massive liver or retrohepatic caval injury is to bypass the flow from the injured area using an extracorporeal circuit (43–46). Therefore, repair can be performed in a bloodless field, but these devices increase the complexity of the operation. Veno-venous bypass technique allows blood to be diverted from the inferior vena cava, with or without portal vein decompression, and drain it into the right atrium either directly or through internal jugular vein or superior vena cava (43–46).

Liver transplantation in severe liver injury

In the last two decades liver transplantation has been reported as an extreme measure in massive hepatic venous and retrohepatic caval injuries followed by uncontrolled bleeding despite repeated previous surgery and acute or progressive liver failure following repair of injury (47, 48). The biggest series was reported by Delis in which three out of four patients survived after liver transplantation (48). A case of extracorporeal repair and "autotransplantation" has also been reported in the case of total avulsion of hepatic veins and a retrohepatic caval injury (49).

COMPLICATIONS FOLLOWING LIVER TRAUMA

Complications of liver injury include bilomas, biliary fistulae, early or late hemorrhage, false aneurysm, arteriovenous fistulae, hemobilia, liver abscess, and liver necrosis (34, 35). Many of these complications could be avoided if debridman of necrotic liver tissue or liver resection were used appropriately. Furthermore, conservative management may cause vascular/or biliary complications, particularly in high-grade injuries (34, 35). Post-traumatic pseudoaneurysm, intrahepatic arteriovenous fistula and hemobilia are a few vascular complications were angioembolization is the first step in the management (50). Symptomatic biloma, liver and intra-abdominal abscesses can also be successfully managed by US/CT-guided percutaneous drainage (50).

CONCLUSION

Trends in management of liver injury have changed and evolved over the last two decades. Hemodynamic status, not the grade of the injury, should dictate the management. CT scan of the abdomen and pelvis is a standard diagnostic modality in hemodynamically stable trauma patients. Extravasation of contrast during CT scans requires further intervention. Unstable patients with an associated abdominal lesion, even in low-grade hepatic trauma, requiring emergency laparotomy. Most patients require minimal treatment to obtain haemostasis. Direct control of bleeding vessels, vascular isolation and damage control surgery are preferred and the most popular approaches. The better understanding of liver trauma, concept of non-operative management and modern surgical approaches, has reduced the morbidity and mortality rate in trauma patients.

List of abbreviations

DCS — Damage control surgery

FAST — Focused assessment by ultrasound for trauma

CT — Computed tomography

ICU — Intensive care unit

AAST — American Association for the Surgery of Trauma

ATLS — Advanced Trauma Life Support

DPL — Diagnostic peritoneal lavage

CS — Intraoperative autotransfusion "Cell Saver"

Sažetak

TUPA TRAUMA JETRE — PREGLED SAVREMENIH DIJAGNOSTIČKIH I TERAPIJSKIH STRATEGIJA

Doklestić Krstina,[1,2] Karamarković Aleksandar[1, 2]

[1] Medicinski fakultet Univerziteta u Beogradu, Srbija
[2] Klinika za Urgentnu hirurgiju, Klinički Centar Srbije, Beograd, Srbija

Jetra je jedan od najčešće povređenih organa kod tupe trauma trbuha. Teške povrede jetre kod politraumatizovanih pacijenata praćene su značajnim morbiditetom i mortalitetom. Terapijski prisup tupim povredama jetre obuhvata ne-hirurške i hirurške metode. Hemodinamska stabilnost, ne stepen povrede jetre, određuju način lečenja. U traumi, CT trbuha i male karlice predstavlja standardnu dijagnostičku metodu kod hemodinamski stabilnog pacijenata. Nedavni napredak radioloških metoda i usavršavanje intezivnog lečenja pomerili su granice terapijskih pristupa povredama jetre. Nehirurški pristup kod povreda jetre kako malog tako i visokog stepena, može biti uspešan u slučaju hemodinamski stabilnog pacijenta. Direktna sutura velikih krvnih sudova, tehnike vaskularne izolacije jetre, i „hirirška kontrola oštećenja“ poboljšali su ishod lečenja kod hemodinamski nestabilnih pacijenata. U ovom radu prikazali smo savremene stavove u lečenju tupe povrede jetre.

Ključne reči: Povrede jetre, tamponada jetre, hirurška kontrola oštećenja, angioembolizacija, hemodinamska nestabilnost, ciljani ultrazvuk abdomena u traumi, kompjuterizovana tomografija, jedinica intenzivne nege.

REFERENCES

1. Feliciano DV. Surgery for liver trauma. Surg Clin North Am. 1989;69: 273–84.

2. Richardson JD, Franklin GA, Lukan JK, et al. Evolution in the management of hepatic trauma: a 25-year perspective. Ann Surg. 200; 232: 324–30.

3. Malhotra AK, Fabian TC, Croce MA, et al. Blunt hepatic injury: a paradigm shift from operative to non-operative management in the 1990s. Ann Surg. 2000; 231: 804–13.

4. Duane TM, Como JJ, Bochicchio GV, et al. Reevaluating the management and outcomes of severe blunt liver injury. J Trauma. 2004; 57: 494–500.

5. Peitzman AB, Richardson JD. Surgical treatment of injuries to the solid abdomi-nal organs: a 50-year perspective from the Journal of Trauma. J Trauma. 2010; 69(5): 1011–21.

6. Lucas CE, Ledgerwood AM. Changing times and the treatment of liver injury. Am Surg. 2000; 66(4): 337–41.

7. Pringle JH. Notes on the arrest of hepatic hemorrhage due to trauma. Ann Surg. 1908; 48: 541–9.

8. Moore EE, Shackford SR, Pachter HL, et al. Organ injury scaling: spleen, liver and kidney. J Trauma. 1989; 29: 1664–5.

9. Moore EE, Shackford SR, Pachter HL, et al. Organ injury scaling: spleen, liver and kidney. J Trauma. 1995; 38: 323–4.

10. Asensio JA, Demetriades D, Chahwan S, et al. Approach to the management of complex hepatic injuries. J Trauma. 2000; 48: 66–9.

11. American College of Surgeons. Advanced Trauma Life Support. St Clair (Chicago); 2004.

12. Hoff WS, Holevar M, Nagy KK, Patterson L, Young JS, Arrillaga A, Najarian MP, Valenziano CP. Eastern Asociation for the Surgery of Trauma. Practice management guidelines for the evaluation of blunt abdominal trauma: the East practice management guidelines work group. J Trauma. 2002; 53(3): 602–15.

13. Root HD, Howser CW, McKinley CR, et al. Diagnostic peritoneal lavage. Surgery. 1965; 57: 633–7.

14. Olsen WR, Redman HC, Hildreth DC. Quantitative peritoneal lavage in blunt abdominal trauma. Arch Surg. 1972; 104: 536–43.

15. Scalea TM, Rodriguez A, Chiu WC, Brenneman FD, Fallon WF, Jr, Kato K, et al. Focused assessment with sonography for trauma (FAST): results from an international consensus conference. J Trauma. 1999; 46:4 66–72.

16. Hsu JM, Joseph AP, Tarlinton Lj, Macken L, Blome S. The accuracy of focused assessment with sonography in trauma (FAST) in blunt trauma patients: Experience of an Australian major trauma service. Injury. 2006; 38: 71–5.

17. Richards JR, Schleper NH, Woo BD, Bohnen PA, McGahan JP. Sonographic assessment of blunt abdominal trauma: a 4 –year prospective Study. J Clin Ultrasound. 2002; 30: 59–67.

18. Catalano O, Lobianco R, Raso MM, Siani A. Blunt hepatic trauma: Evaluation with contrast-enhanced sonography. J Ultrasound Med. 2005; 24: 299–310.

19. Puranik SR, Hayes JS, Long J, et al. Liver enzymes as predictors of liver damage due to blunt abdominal trauma in children. South Med J. 2002; 95: 203–6.

20. Stassen NA, Lukan JK, Carrillo EH, et al. Examination of the role of abdominal computed tomography in the evaluation of victims of trauma with increased aspartate aminotransferase in the era of focused abdominal sonography for trauma. Surgery. 2002; 132: 642–6.

21. Srivastava AR, Kumar S, Agarwal GG, et al. Blunt abdominal injury: serum ALT-A marker of liver injury and a guide to assessment of its severity. Injury. 2002; 38: 1069–74.

22. Federle MP, Goldberg HI, Kaiser KA, et al. Evaluation of abdominal trauma by computed tomography. Radiology. 1981; 138: 637–44.

23. Poletti PA, Mirvis SE, Shanmuganathan K, Killeen KL, Coldwell D. CT criteria for management of blunt liver trauma: Correlation with angiographic and surgical findings. Radiology. 2000; 216: 418–27.

24. Becker CD, Mentha G, Terrier F. Blunt abdominal trauma in adults: role of CT in the diagnosis and management of visceral injuries. Eur Radiol. 1998; 8: 553–62.

25. Yoon W, Jeong YY, Kim JK, Seo JJ, Lim HS, Shin SS, et al. CT in blunt liver trauma. Radiographics. 2005; 25: 87–104.

26. Soto JA, Anderson SW. Multidetector CT of blunt abdominal trauma. Radiology. 2012; 265(3): 678–93.

27. Taourel P, Vernhet H, Suau A, Granier C, Lopez FM, Aufort S, et al. Vascular emergencies in liver trauma. Eur J Radiol. 2007; 64: 73–82.

28. Cuff RF, Cogbill TH, Lambert PJ. Non-operative management of blunt liver trauma: the value of follow-up computed tomography scans. Am Surg. 2000; 66: 232–6.

29. Inoguchi H, Mii S, Sakata H, et al. Intrahepatic pseudoaneurysm after surgical hemostasis for a delayed hemorrhage due to blunt liver injury: report of case. Surg Today. 2001; 31: 367–70.

30. Trunkey DD. Hepatic trauma: Contemporary management. Surg Clin North Am. 2004; 84: 437–50.

31. Croce MA, Fabian TC, Menke PG, et al. Non-operative management of blunt hepatic trauma is the treatment of choice for hemodynamically stable patients: results of a prospective trial. Ann Surg. 1995; 221: 744–55.

32. Johnston JW, Gracias VH, Reilly PM. Hepatic angiography in the damage control population. J Trauma. 2001; 50: 176.

33. Carrillo EH, Spain DA, Wohltmann CD, Schmieg RE, Boaz PW, Miller FB, et al. Interventional techniques are useful adjuncts in nonoperativemanagement of hepatic injuries. J Trauma. 2000; 46: 619–24.

34. Kozar RA, Moore JB, Niles SE, Holcomb JB, Moore EE, Cothren CC, Hartwell E, Moore FA. Complications of nonoperative management of high-grade blunt hepatic injuries. J Trauma. 2005; 59: 1066–71.

35. Mohr AM, Lavery RF, Barone A, Bahramipour P, Magnotti Lj, Osband AJ, Sifri Z, Livingston DH. Angiographic embolization for liver injuries; low mortality, high morbidity. J Trauma. 2003, 55: 1077–82.

36. Velmahos GC, Toutouzas KG, Radin R, Chan L, Demetriades D. Nonoperative treatment of blunt injury to solid abdominal organs: A prospective study. Arch Surg. 2003; 138: 844–51.

37. Fang JF, Chen RJ, Lin BC, Hsu YB, Kao JL, Chen MF. Blunt hepatic injury: Minimal intervention is the policy of treatment. J Trauma. 2000; 49: 722–8.

38. Asensio JA, Demetriades D, Chahwan S, Gomez H, Hanpeter D, Velmahos G, et al. Approach to the management of complex hepatic injuries. J Trauma. 2000; 48: 66–9.

39. Achneck HE, Sileshi B, Jamiolkowski RM, Albala DM, Shapiro ML, Lawson JH. A comprehensive review of topical hemostatic agents: efficacy and recommendations of use. Ann of surg. 2010; 251: 217–28.

40. van Gulik TM, de Graaf W, Dinant S, Busch OR, Gouma DJ. Vascular occlusion techniques during liver resection. Dig Surg. 2007; 24(4): 274–81.

41. Karamarković AR, Popović NM, Blagojević ZB, Nikolić VT, Gregorić PB, Bukurov MN, Djukić VR, Bajec DjD. Damage control surgery in abdominal trauma. Acta Chir Iugosl. 2010; 57(1): 15–24.

42. Brown CV, Foulkrod KH, Sadler HT, et al. Autologous blood transfusion during emergency trauma operations. Arch Surg. 2010; 145(7): 690–4.

43. Shaw BW, Jr, Martin DJ, Marquez JM, Kang YG, Bugbee AC, Jr, Iwatsuki S, et al. Venous bypass in clinical liver transplantation. Ann surg. 1984; 200: 524–34.

44. Horwitz JR, Black T, Lally KP, Andrassy RJ. Venous bypass as an adjunt for the management of a retrohepatic venous injury in a child. J Trauma. 1995; 39: 584–5.

45. Baumgartner F, Scudamore C, Nair C, Karusseit O, Hemming A. Venovenous bypass for major hepatic and caval trauma. J Trauma. 1995; 39: 671–3.

46. Kaoutzanis C, Evangelakis E, Kokkinos C, Kaoutzanis G. Successful repair of injured hepatic veins and inferior vena cava following blunt traumatic injury, by using cardiopulmonary bypass and hypothermic circulatory arrest. Interact Cardiovasc Thorac Surg. 2011; 12(1): 84–6.

47. Ringe B, Pilchmayr R. Total hepatectomy and liver transplantation: a life-saving procedure in patients with severe lever trauma. Br J Surg. 1995; 82: 837–9.

48. Delis SG, Bakoyiannis A, Selvaggi G, Weppler D, Levi D, Tzakis AG. Liver transplantation for severe hepatic trauma: Experience from a single center. World J Gastroenterol. 2009; 15: 1641–4.

49. Boggi U, Vistoli F, Del Chiaro M, Signori S, Sgambelluri F, Roncella M, Filipponi F, Mosca F. Extracorporeal repair and liver autotransplantation after total avulsion of hepatic veins and retrohepatic inferior vena cava injury secondary to blunt abdominal trauma. J Trauma. 2006; 60(2): 405–6.

50. Goffette P, Pierre, Laterre Pierrre. Franciscois Traumatic injuries: Imaging and intervention in post-traumatic complication (delayed intervention). Eur Radiol. 2002; 12: 994–1021.

Correspondence to/Autor za korespondenciju
Krstina Doklestić, Clinical Teaching Assistant
Faculty of Medicine, University of Belgrade, Serbia
Clinic for Emergency Surgery, Clinical Center of Serbia
Pasterova 2, Belgrade
Serbia
Tel: +381113662260
e-mail: krstinadoklestic@gmail.com