

## PULMONARY AMEBIASIS COMPLICATED WITH MASSIVE LEFT EMPYEMA AND RESPIRATORY FAILURE: A CASE REPORT

Dewi P Kristin,<sup>1,2</sup> Suci D Yulia,<sup>1,2</sup> Dewi P Ivana,<sup>1,3</sup> Iswanto Iswanto<sup>4</sup>

<sup>1</sup> Faculty of Medicine, Universitas Airlangga, Surabaya, Indonesia

<sup>2</sup> Department of Pulmonology and Respiratory Medicine, Dr. Soetomo General Hospital, Surabaya, Indonesia

<sup>3</sup> Department of Cardiology and Vascular Medicine, Dr. Soetomo General Hospital, Surabaya, Indonesia

<sup>4</sup> Department of Pulmonology and Respiratory Medicine, Bethesda Academic Hospital, Yogyakarta, Indonesia

Primljen/Received 11. 02. 2020. god.

Prihvaćen/Accepted 02. 04. 2020. god.

**Abstract: Introduction:** Amebiasis is defined as a parasitic infection with the protozoan *Entamoeba histolytica*. Amebiasis in pulmonary and pleural tissue is the second common location of extraintestinal amebiasis after amoebic liver abscess. Pulmonary and pleural amebiasis happens in 2-3% of invasive amebiasis patients with mortality rate 5-16%.

**Case:** We report a 22-year-old man with the chief complaint of dyspnea for one week. The patient also felt pain in the left chest, had productive cough and fever. He had a history of dysentery one month ago. BGA evaluation confirmed patient had respiratory failure type 1 with PCO<sub>2</sub> 35 and PO<sub>2</sub> 46.1. Thoracentesis was performed, the result was brown milk (anchovy paste) color and pleural fluid analysis revealed positive *Entamoeba histolytica*. Antimicrobial therapy and drainage were given with excellent response.

**Conclusion:** Pulmonary and pleural amebiasis is an uncommon disease, usually occurring on the right side of the lung compared to the left side and rarely causing respiratory failure. Pulmonary amebiasis is a life-threatening, but treatable, condition. Antimicrobial therapy and drainage is an important strategy in pulmonary amebiasis management.

**Keywords:** Pulmonary amebiasis, massive empyema, respiratory failure.

### INTRODUCTION

*Entamoeba histolytica* is an intestinal protozoan. Amoebic infection (amebiasis) is defined by the World Health Organization (WHO) as *Entamoeba histolytica* infection with or without clinical manifestations (1). Amebiasis is the third ranking cause of death worldwide due to parasitic infections after malaria and schisto-

somiasis (2). It is estimated 40,000-100,000 mortality occurs in 40-50 million amebiasis patients each year (3). Amebiasis occurs in 12% of the world's population or 50% of the population in tropical and subtropical regions. The incidence of amebiasis is quite high in developing countries such as Mexico, South and West Africa, South and Central America, Bangladesh, Thailand, India, Vietnam, and Indonesia. Fecal-oral transmission happens via fecal contamination of food and water. Lack of sanitary conditions and poor hygiene predispose to spread the disease (1, 4).

Pulmonary and pleural tissue are the second common location of extraintestinal amebiasis after amoebic liver abscess. Pleuropulmonary amebiasis occurs in 2-3% of invasive amebiasis patients with a mortality rate of 5-16% (3). Pleuropulmonary usually occurs when a right lobe liver abscess ruptures through the diaphragm and produces an empyema in the right hemithorax. We reported a rare case of pulmonary amebiasis complicated with respiratory failure and massive empyema in left hemithorax.

### CASE REPORT

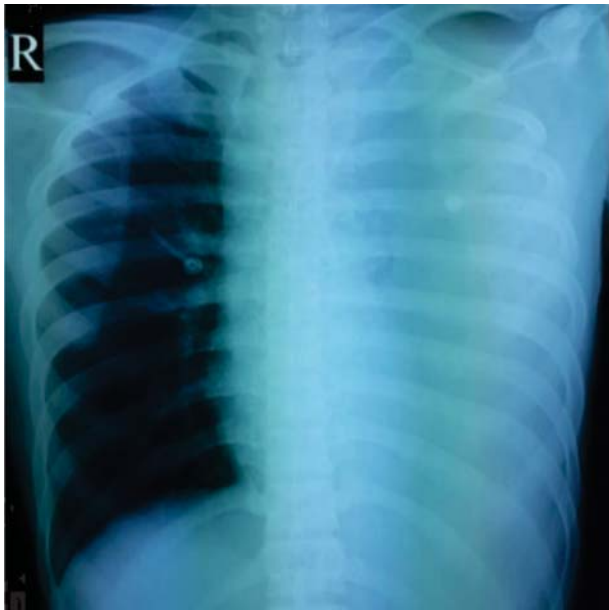A 22-year-old man came to the Emergency Department with chief complaint of dyspnea for one week. The patient also felt pain in the left chest, had productive cough and fever. He had a history of dysentery dating one month ago. He denied any history of jaundice, nausea, vomiting, and abdominal pain. He went to primary healthcare and was prescribed ciprofloxacin for three days.

From the physical examination, he was compositus, anemic, and sweaty. Vital sign results were blood pressure 100/70 mmHg, pulse 112 bpm, respira-

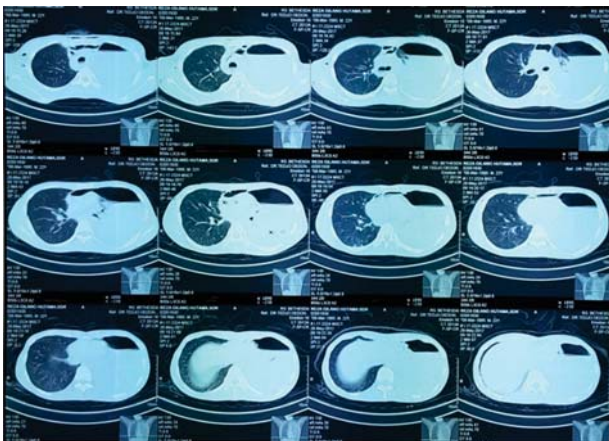
tion rate 40x/min, temperature 39.2 °C, SpO<sub>2</sub> 81%. Chest examination revealed significant decrease left side motion and tactile vocal fremitus, dullness percussion, auscultation sound was not heard, normal heart sound with no murmurs and gallops. Abdominal examination was soft and no evidence of hepatomegaly.

Laboratory report were Hb 9.6g/dl, WBC 13.83 x 10<sup>3</sup>, platelet 350 x 10<sup>3</sup>, neutrophil 92.2% random glucose 114 mg/dl. BGA evaluation confirmed pH 7.518, PCO<sub>2</sub> 35, PO<sub>2</sub> 46,1, HCO<sub>3</sub> 29.9, and BE 5.5. Stool examination suggested *Entamoeba histolytica* infection.

Chest x-ray examination was taken which showed a left total consolidation (Figure 1). CT scan thorax



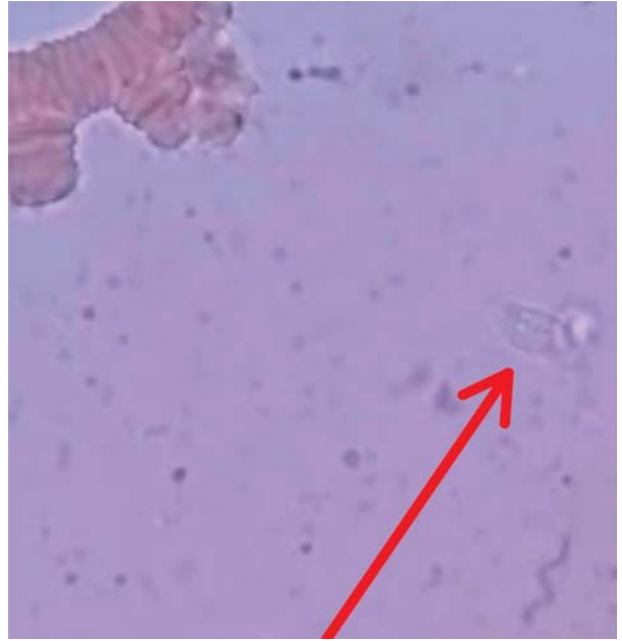**Figure 1.** Chest X-ray homogenous opacity in left hemithorax



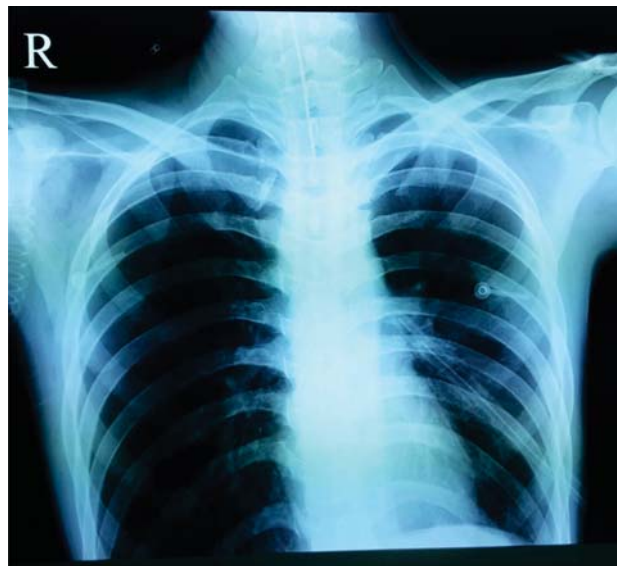**Figure 2.** CT-scan thorax



**Figure 3.** Pleural fluid anchoovy paste



**Figure 4.** Microscopic view of *Entamoeba histolytica*



**Figure 5.** Chest X-ray after WSD

showed air-fluid level with left hemithorax pleural effusion, suspect left massive empyema (Figure 2). ECG showed sinus tachycardia. USG abdomen revealed solitary abscess in left quadrant size 18mm x 17mm.

Thoracocentesis was performed, the result was brown milk (anchoovy paste) color (Figure 3). Hence an emergency intercostal chest drain (WSD) was placed in the left side which drained about 1250 ml. WSD was installed for four days and pleural fluid analysis revealed positive *Entamoeba histolytica* (Figure 4).

The patient was diagnosed with pulmonary amebiasis complicated with massive left empyema, respiratory failure, and anemia. Patient was hospitalized in intensive care unit (ICU), breathing with ventilator support for three days, and installation of WSD for four

days. Evaluation of chest x-ray after WSD revealed increased bronchovascular pattern with minimal air bronchogram (Figure 5).

The patient had medication with metronidazole 3 x 500 mg intravenous for five days and continued 3 x 500 mg orally for 10 days, levofloxacin 750 mg intravenous, ambroxol 3 x 30 mg, and sulfas ferosus. The patient had good response from medical therapy.

## DISCUSSION

The pathogenesis of amebiasis occurs when parasites attach to the mucus layer, without effective defense from the host immune system. In a normal host immune response, IgA can prevent pathogens from sticking and penetrating the mucus layer. Intestinal epithelial cells identify pathogens through the toll-like receptor and activate NF- $\kappa$ B which will produce inflammatory cytokines. Interferon gamma (IFN- $\gamma$ ) plays an important role in defense against infection. Macrophages and neutrophils activated by IFN- $\alpha$  will go to the infection site and, thus, produce nitric oxide (NO) and reactive oxygen species (ROS), which will kill trophozoites (4).

Amebiasis generally occurs in the form of intestinal involvement. It can also present as an extra-intestinal disease. Extra-intestinal site of amoebiasis is an amoebic liver abscess (3-9% of all cases) and even more rare as pulmonary, cardiac, and brain involvement. Amoebiasis in the lung and pleural tissues is the second extra-intestinal amoebiasis. Pulmonary and pleural (pleuropulmonary) amoebiasis occur in 2-3% patients, and 6-40% of patients also have an amoebic liver abscess (3,5). Distribution of *entamoeba* infection in the chest is through: 1. independent liver abscess and hematogenous lung abscess (10.4%), 2. hematogenous spread without liver involvement (14.3%), 3. empyema extending from liver (17.6%), 4. bronchospastic fistula (19.6%), and 5. abscess extending from liver (37.2%) (2). The invasive amebiasis mortality rate was 5-16% and can increase to 80% if not treated.

Pulmonary amebiasis occurs from several mechanisms, including rupture of the right lobe liver abscess through the diaphragm causing empyema, hematogenous, and lymphogenic spread. The most common mechanism is a direct rupture of amoebic liver abscess via the diaphragm, which leads to empyema in the chest cavity. The second is through hematogenous spread from the large intestine via the hemorrhoidal vein, superior mesenteric veins, and inferior vena cava to the lung and pleura. In our patient, pulmonary amoebiasis without liver involvement occurred sporadically as a result of hematogenous spread from a primary site, the colon, which was the most probable route (3, 6).

*Entamoeba* infections are usually asymptomatic. The risk factors are young age, genetic susceptibility,

atrial septal defect with left to right shunt, pregnancy, corticosteroid treatment, immune status, malignancy, chronic alcoholism, and malnutrition (5, 7). Pleuropulmonary amebiasis is sometimes mimics other illnesses. The differential diagnoses are: bacterial lung abscess, pulmonary tuberculosis, carcinoma of the lung, malaria and schistosomiasis endemic areas..

Pulmonary amebiasis diagnosis is sometimes difficult since there are various clinical manifestations. In addition to clinical manifestation, laboratory tests and imaging modalities need to be done. The exact diagnosis was established by *Entamoebahistolytica* finding in microscopic examination (7). Amebiasis clinical manifestation occurs in the form of intestinal involvement as acute or subacute colitis, with symptoms ranging from abdominal pain, mild to severe diarrhea, and bloody stools (5). Patients may initially present with fever only (1, 5). In this case, the patient had a history of dysentery which may lead to the port de entry of pulmonary amebiasis.

Blood chemistry or hematologic testis sometimes not helpful in pulmonary amebiasis diagnosis. Neutrophilic leucocytosis ( $> 15,000/\text{mm}^3$ ), invariably elevation of erythrocyte sedimentation rate (ESR), and normocytic normochromic anemia are usually present. Liver function tests are sometimes within normal limit even when hepatic complication also happen with pulmonary amebiasis (2). Confirmation with laboratories testing should be pursued by stool microscopy. Trophozoites and cysts usually identify via light microscopic examination (5). Immunological tests, such as enzyme-linked immunosorbent assay (ELISA) and indirect hemagglutination assay (IHA), may detect *E. histolytica* antibodies in 85-95% of patients (5, 7).

Radiographic imaging, such as computed tomography (CT) scan, magnetic resonance imaging (MRI), chest ultrasonography (USG), and X-ray, are sometimes needed (7). From chest X-ray, we can find right lower and middle lobes cavitating lesion with homogeneous opacity seen in lateral view, pleural effusion, basilar pulmonary infiltrated with focal atelectasis, and elevated right hemidiaphragm (5). Pleural effusion occurs in 62.5% of cases. When there is bronchopleural fistula, a hydropneumothorax may be seen (2). MRI and CT scan have excellent sensitivity to detect liver abscess (5, 6). USGis used to monitor extra-intestinal amebiasis treatment (2).

In some studies, catheter drainage or needle aspiration are needed to diagnose pleuropulmonary amebiasis (7). The classical characteristics and colors of amoebic pus are reddish-brown, thick, opaque, and resembling "chocolate sauce" or "anchovy paste". Expecterated pus is usually "anchovy sauce" color. Aspirated pus is usually sterile and expecterated pus sometimes contains a few organisms (2).

Amoebiasis is a treatable disease, but delay in the diagnosis may lead to serious complications. This case was complicated by left side empyema and respiratory failure (respiration rate 40x/min and blood gas analysis result). In general, amoebic empyema should be aspirate (5). Drainage of pleural effusion resolves rapidly with antimicrobial therapy. Drug of choice is metronidazole (750 mg oral, three times daily for 7-10 days). Metronidazole is a nitro-imidazole derivative that can kill the trophozoites. When given orally, it is soon absorbed and immediately seeps into the tissue through the diffusion process. The drug's mechanism is activated by the reduction of the nitro group and produces radical metronidazole. Radical metronidazole will interact with proteins causing parasitic death. In this case, we gave metronidazole 500 mg, 3x daily for 15 days. Empyema requires pleural puncture, installation WSD four days and decortication is done to prevent recurrent and chronic infection. For respiratory failure, we performed ventilator support for three days. Response to treatment was good.

## CONCLUSION

Pulmonary and pleural amoebiasis is an uncommon disease, usually occurring on the right side of the lung compared to the left side and rarely causing respiratory failure. Pulmonary amoebiasis is a life-threatening, but

treatable, condition. Antimicrobial therapy and drainage is an important strategy in pulmonary amoebiasis management. *Entamoeba histolytica* infection should be suspected as a possible cause in the differential diagnosis in young patients, especially in patients from endemic areas.

## Abbreviations

**BGA** — blood gas analysis  
**CT** — computed tomography  
**ECG** — electrocardiography  
**IFN- $\gamma$**  — Interferon gamma  
**MRI** — magnetic resonance imaging  
**NO** — nitric oxide  
**ROS** — reactive oxygen species  
**USG** — ultrasonography  
**WHO** — World Health Organization  
**WSD** — water sealed drainage

**Conflict of Interests:** The authors declare that there are no conflicts of interest related to this article.

**Funding:** None

## Licensing

This work is licensed under a Creative Commons Attribution 4.0 International (CC BY 4.0) License.

## Sažetak

# PLUĆNA AMEBIJAZA KOMPLIKOVANA MASIVNIM LEVOSTRANIM EMPIJEMOM I RESPIRATORNOM INSUFICIJENCIJOM: PRIKAZ SLUČAJA

P Dewi Kristin,<sup>1,2</sup> Suci D Yulia,<sup>1,2</sup> Dewi P Ivana,<sup>1,3</sup> Iswanto Iswanto<sup>4</sup>

<sup>1</sup> Faculty of Medicine, Universitas Airlangga, Surabaya, Indonesia

<sup>2</sup> Department of Pulmonology and Respiratory Medicine, Dr. Soetomo General Hospital, Surabaya, Indonesia

<sup>3</sup> Department of Cardiology and Vascular Medicine, Dr. Soetomo General Hospital, Surabaya, Indonesia

<sup>4</sup> Department of Pulmonology and Respiratory Medicine, Bethesda Academic Hospital, Yogyakarta, Indonesia

**Uvod:** Amebijaza se definiše kao parazitna infekcija protozoozom *Entamoeba histolytica*. Amebijaza u plućnom ili pleuralnom tkivu je druga najčešća lokalizacija ekstraintestinalne amebijaze nakon hepatičnog apscesa izazvanog amebijazom. Plućna i pleuralna amebijaza se javlja u 2-3% invazivne amebijaze kod pacijenata, sa stopom mortaliteta od 5-16%.

**Prikaz slučaja:** Prikazujemo slučaj 22-ogodišnjeg mladića, koji se nedelju dana žalio na teškoće sa disanjem. Pacijent je takođe osećao bolove sa leve strane grudnog koša. Imao je produktivan kašalj i temperaturu. Navodi da je mesec dana pre pregleda imao dizenteriju. Gasne analize potvrdile su da kod pacijenta postoji respiratorna insuficijencija tip 1 sa

PCO<sub>2</sub> 35 i PO<sub>2</sub> 46.1. Urađena je torakocenteza i dobijena tečnost braonkaste boje, a analiza pleuralne tečnosti potvrđuje *Entamoeba histolytica*-u. Antimikrobna terapija i torakalna drenaža pokazale su zadovoljavajući efekat.

**Zaključak:** Plućna i pleuralna amebijaza nisu retke forme bolesti. Češće se javljaju sa desne strane pluća, u poređenju sa levom stranom i retko izazivaju respiratornu insuficijenciju. Plućna amebijaza je životno ugrožavajuća bolest, koja je pak izlečiva. Antimikrobna terapija i drenaža su veoma bitne u lečenju plućne amebijaze.

**Cljučne reči:** pulmonalna amebijaza, masivni empijem, respiratorna insuficijencija.

## REFERENCES

1. Chitra L, Huggins JT, Sahn SA. Parasitic diseases of the pleura. *Am J Med Sci*. 2013; 345(5): 385–9.
2. Shamsuzzaman SM, Hashiguchi Y. Thoracic amebiasis. *Clin Chest Med*. 2002; 23(2): 479–92.
3. Lichtenstein A, Kondo AT, Visvesvara GS, Fernandez A, Paiva EF, Mauad T et al. Pulmonary amoebiasis presenting as superior vena cava syndrome. *Thorax*. 2005; 60(4): 350–2.
4. Liu Y, Ying Y, Chen C, Hu Y, Yang F, Shao L, et al. Primary pulmonary amebic abscess in a patient with pulmonary adenocarcinoma: a case report. *Infect Dis Poverty*. 2018; 7(1): 34.
5. Zakaria A, Bayan, Al Asad K. Case report primary pulmonary amebiasis complicated with multicystic empyema. *Case Rep Pulmonol*. 2016; 2016: 8709347. doi: 10.1155/2016/8709347.
6. Danny Darlington C, Fatima Shirly Anitha G. Ruptured amoebic liver abscess with empyema thoracis - a case report. *Int Surg J*. 2017; 4(5): 1801–2.
7. Nasrullah A, Haq S, Ghazanfar H, Sheikh AB, Akhtar A, Zafar R et al. A unique case of empyema secondary to amoebic liver abscess. *Cureus*. 2017; 9(6). e1377. doi: 10.7759/cureus.1377.

### Correspondence to/Autor za korespondenciju

Dewi Kristin

Faculty of Medicine, Universitas Airlangga, Surabaya, Indonesia

email: kristin\_purnama\_d@yahoo.co.id