

## PATTERNS OF SUPERIOR ARTICULAR FACET AND MORPHOMETRIC STUDY OF NEPALESE DRY CALCANEI

Dhakal Arun,<sup>1</sup> Adhikari Prashant,<sup>2</sup> Khan G. Anwer,<sup>3</sup> Gautam Aajeevan<sup>3</sup>

<sup>1</sup> Department of Anatomy, Birat Medical College and Teaching Hospital, Biratnagar, Nepal

<sup>2</sup> Department of Orthopaedics, Grande International Hospital, Kathmandu, Nepal

<sup>3</sup> Department of Anatomy, Chitwan Medical College, Bharatpur, Nepal

Primljen/Received 22. 03. 2018. god.

Prihvaćen/Accepted 10. 04. 2018. god.

**Abstract: Introduction:** The three important articulating facets in the superior aspect of the calcaneum are the anterior, middle and posterior articulating facet. Descriptions of the posterior talar facet on the dorsum of the calcaneus are similar. However, there are differences when facet for the head of the talus on the calcaneus is considered. Four types (pattern I, II, III, IV) of calcaneus having different talar facets are reported in the literature.

**Objective:** This study aims to describe the calcaneal bone by measuring its dimensions and determining the variations of talar articulating facet.

**Materials and methods:** Overall 142 calcanei (68 right, 74 left) with unidentified gender, were assessed. Vernier calipers and Goniometry were used.

**Results:** In this study Type I calcaneus (56.34 %) was the most prevalent type with Type II calcaneus (42.25 %) as the second most common type followed by Type IV (1.41 %) as the third frequently found pattern of calcaneus.

**Conclusion:** Type I calcaneus was the most frequent type in the Nepalese showing similarity to the results of the studies performed in Spanish, American, African and various Indian population. Bohler's angle of the right and left calcanei was  $34.92^\circ \pm 8.09^\circ$  and  $35.4^\circ \pm 7.30^\circ$  respectively. Development of database of calcaneal measurements in various populations is recommended.

**Key words:** Calcanei, Talar articular facets, Nepalese.

### INTRODUCTION

Calcaneus is the longest, largest and one of the major weight bearing tarsal bones forming the talocalcaneal joint with the talus. This joint is also termed as subtalar joint where eversion and inversion of the foot

takes place (1). There are three facets for synovial joints between the talus and calcaneus, anterior, middle and posterior talar facet with variations seen in the arrangement of these facets as described in this study. Calcaneal fractures are the most commonly encountered tarsal fractures mostly involving the intra-articular subtalar joint (2). The majority of bony coalition commonly involves the middle talar facet of the talocalcaneal joint, also a common cause of painful flatfoot (3). Morphometric values of calcanei are essential for the science of anatomy, treatment and diagnosis procedures on orthopedic surgery, kinesiology, physical treatment and rehabilitation sessions (4). Structural dissimilarity of the calcanei has an impact on the fixed and kinetic dynamics of the foot. The relationship of talus and the calcaneus should be thoroughly considered during the treatment of talocalcaneal coalition, congenital club foot, subtalar instability, cases of severe pronation, valgus deformities, designing subtalar implants and others (5, 6, 7). Bohler's angle is commonly evaluated via radiography during calcaneal fractures for proper diagnosis and treatment. There is a significant loss or decrease of this angle in a severe case of heel fracture (8, 9, 10).

With the means of facet variation and bone dimension, this study attempts to describe the calcaneus bone of Nepalese race.

### MATERIALS AND METHODS

A total of 142 dried calcanei (68 right, 74 left) without major defects and unidentified gender were assessed. All the bones were classified with Type I, II and IV identified as the predominant finding of our study. Pattern of articular facet on the superior aspect of the calcaneus was classified as follows:

Type I: Anterior and middle fused and posterior separate. (Figure 1)

Type II: Anterior, middle, and posterior facets separate. (Figure 2)

Type III: Anterior facet absent and other two present.

Type IV: Anterior, middle and posterior facet fused. (Figure 3)

Following measurements on the calcaneus were performed using Vernier Calipers:

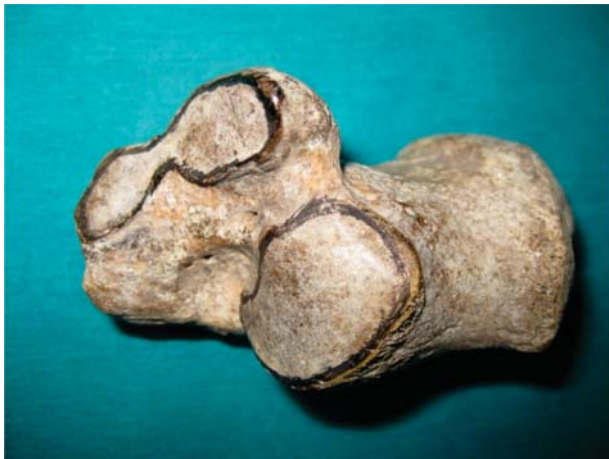a) Maximum anterior posterior length: optimum anterior and optimum posterior extension of the calcaneus (Figure 4a)

b) Maximum transverse diameter: optimum medial and lateral extensions of the calcaneus (Figure 4b)

c) Maximum vertical length: optimum extension of superior margin of posterior facet to the base of the calcaneus (Figure 4c)

Boehler's angle: Fixing the calcaneus in anterior posterior axis, the angles were measured by setting up the arms of the goniometry at following points: (Figure 5)

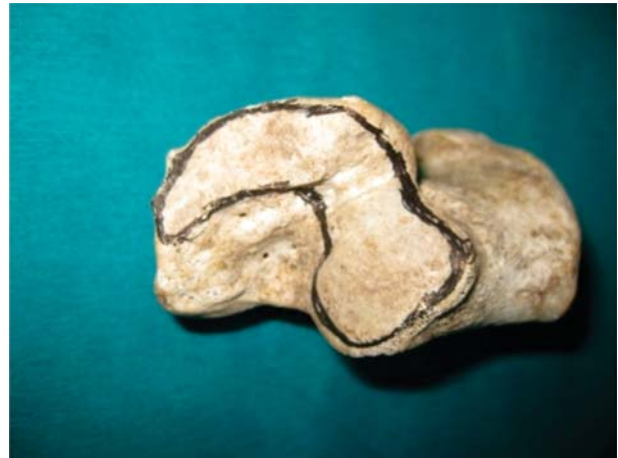I. Superior edge of anterior process to superior edge of posterior facet.



**Figure 1** — Type I articular facet on the superior aspect of the calcaneus



**Figure 2** — Type II articular facet on the superior aspect of the calcaneus



**Figure 3** — Type IV articular facet on the superior aspect of the calcaneus



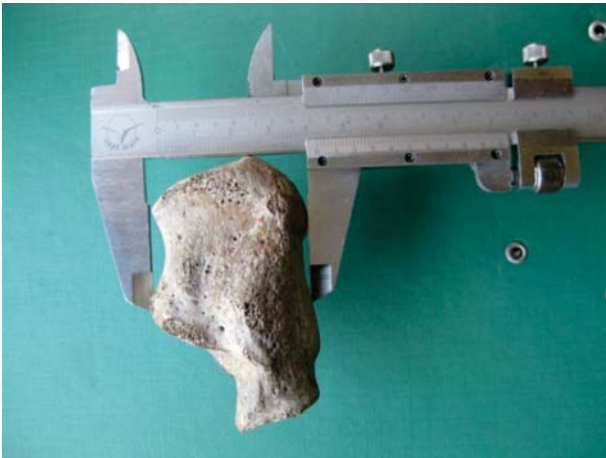**Figure 4(a)** — Measuring maximum anterior posterior length of the calcaneus




**Figure 4 (b)** — Measuring maximum transverse diameter of the calcaneus

II. Superior edge of tuberosity to superior edge of posterior facet.

SPSS software for windows was used for statistical analysis. Results are expressed in mean  $\pm$  SD (standard deviation).



**Figure 4 (c)** — Measuring maximum vertical length of the calcaneus



**Figure 5** — Measuring the Boehler's angle

**RESULTS**

The talar articular facets in 142 dry calcanei were classified into four different types with three types being identified in this study (Table 1) and the same com-

pared to that of other studies (Table 2). Type I (56.34%) was recognized as the most prevalent type (Figure 1), followed by Type II (42.25%), Figure 2 and Type IV (1.41%) pattern (Figure 3). None of the observed calcanei showed Type III configuration.

**Table 1.** Classification of talar articulating facet of calcanei and its percentage

Pattern of articular facet	Side (n)		Total (n = 142)
	Right (68)	Left (74)	
Type I	46 (57.5%)	34 (42.5%)	80 (56.34%)
Type II	23 (38.33%)	37 (61.67%)	60 (42.25%)
Type III	0 (0%)	0 (0%)	0 (0%)
Type IV	0 (0%)	2 (100%)	2 (1.41%)

**Table 2.** Comparison of pattern of talar articulating facet between Nepalese and that reported by other investigators

Study	Year	Country	n (sample size)	I%	II%	III%	IV%
Gupta <i>et al.</i> <sup>(14)</sup>	1977	India	401	66.8	25.9	5.2	1.9
Campos and Pellico <sup>(15)</sup>	1986	Spain	176	53.4	46.5	0	0
El-Eishi <sup>(11)</sup>	1974	Egypt	200	49	40	11	0
Bunning and Barnett <sup>(5,13)</sup>	1963, 1965	British	194	32.9	67	0	0
Bunning and Barnett <sup>(5,13)</sup>	1963, 1965	Africans	492	63.4	37.7	0	1
Uygur <i>et al.</i> <sup>(4)</sup>	2009	Turkey	221	58	39.3	0	0
Verhagen FD <sup>(12)</sup>	1993	Americans	191	54.4	26.7	18.85	0
Nepalese (Present study)	2017	Nepal	142	56.34	42.25	0	1.41

**Table 3.** Morphometric measurements of the calcaneus

Measurements	Right calcaneus, mean ± SD (mm), n = 68	Left calcaneus, mean ± SD (mm), n = 74	p value	Total, mean ± SD (mm), n = 142
Anterior posterior length	70.22 ± 7.1	70.47 ± 8.79	0.96	70.35 ± 7.64
Transverse length	38.36 ± 4.17	38.77 ± 3.87	0.87	38.58 ± 3.81
Vertical height	44.48 ± 5.32	43.83 ± 7.87	0.88	44.13 ± 6.51

**Table 4.** *Boehler's angle estimation*

Boehler's angle	Right (n = 68)	Left (n = 74)	p-value
	34.92° ± 8.09°	35.4° ± 7.30°	0.92

Morphometric measurements and their findings are shown in Table 3. Boehler's angle in the right and left calcanei are shown in Table 4.

## DISCUSSION

The common pattern of the articular facets on the superior surface of the calcaneus for the head of the talus in our study is Type I (56.34%) and II (42.25%) as shown in Table 1. From Table 2 it is clear that the outcome of our study is consistent with the studies done by different authors previously. The prevalence of Type III pattern of calcanei was observed to a greater degree in Egyptians in an article by EI-Eishi (11) and Americans in a study by Verhagen FD (12) implying that the facets could be genetically determined as stated by Bunning and Barnett (13). A relatively small sample of Type IV patterned facet was common to the Africans (5), Indians (14) and our study. This finding may possibly be used as a racial characteristic. Additionally, Table 2 reveals, that in the Americans (12), Africans (5, 13) and Indians (14) the percentage of Type II is almost about half of Type I, whereas Spanish (15) and Egyptian (11) population has equal preponderance of Type I and Type II facet. Interestingly in the British (5, 13), Type II facets are almost twice as frequent as Type I, explaining another probable racial attribute. Geographical region, human habits like squatting, use of shoes and genetic factors may be the predisposing cause to the variations observed in the facets, with Type I more common in females (13).

The configuration of talar articulating facet also plays a key role in the stability of the subtalar joint is consistent with Bruckner's hypothesis that the joints with two facet configuration are comparatively more stable (16). This stability also depends on the height of the longitudinal arch, which is usually referred to as a cavus foot (16, 17). Computerized tomography scans show that the flat foot (planus foot) has no anterior sustentaculum tali facet (18). These findings suggests that the population with continuous facet and medial only facet pattern of the sustentaculum tali may be at a greater risk for subtalar joint instability than those with two facet type pattern (12). Furthermore, study by Chavan et al. suggests that leggedness, right or left could also be the contributing factor to the development of talar articulating patterns seen in human calcanei (19).

Calcaneal fracture accounts for 33% of foot fractures with 100% association to the posterior talocalcaneal facet in intra-articular fractures (20). The evaluation of vertical length of calcaneus may be a supportive criterion

of calcaneus fractures (21). In our study the height, transverse and anterior-posterior length of right and left calcaneus was insignificant when compared to each other (Table 3). The given dimensions may provide a landmark for postoperative assessment of status of fractured calcanei.

Decompression fractures particularly alters Boehler's angle. Preserving normal Boehler's angle postoperatively demonstrates surgical success. Study by Khoshhal et al. in the Saudi population found the mean Boehler's angle to be 31.21° not related to age, gender, or side of body (9). Similarly in the study by Uygur et al. the Boehler's angles of right and left calcanei were found as mean 30.8° ± 4.9° and 30.09° ± 5°, respectively with left Boehler's angle correlating with the left vertical length of the calcaneus (4). The mean Bohler's angle of the right and left calcanei estimated in our study was somewhat greater than these studies with the similarity that Boehler's angle did not relate to the sides of calcanei (Table 4). When Boehler's angles of congenital clubfoot were compared to the normal side by Kalenderer et al. no differences were noted between them (22). The mean Boehler's angle in their study measured 35.2° which was close to that of our study.

Bohler's angle has a significant prognostic value in terms of predicting morbidity of calcaneal fractures. There was much poorer two year outcome regardless of treatment of fractures with a markedly diminished Bohler's angle (8). Also, significant correlation between preoperative Böhler's angle and the injury severity of displaced intra-articular calcaneal fractures was observed with only the postoperative Böhler's angle parameters found to have a significant correlation with functional recovery (23). Due to the lack of studies in Boehler's angle involving different population group, development of database for reference purpose, prognosis and treatment especially during postoperative angle measurements could be recommended.

## CONCLUSION

Proper management (internal and external fixation and surgical procedures) of various conditions of the foot like deformities, fractures, arthritis etc demands the understanding of the knowledge of size and shape and relationship of the talus and calcaneus with each other and other bones of the foot. The dimensions of the calcaneus are evaluated. Type I calcaneus was determined as the most frequent type in the Nepalese showing similarity to the results of the studies performed in Spanish, American, African and various Indian

population. Bohler's angle of the right and left calcanei was  $34.92^\circ \pm 8.09^\circ$  and  $35.4^\circ \pm 7.30^\circ$  respectively. Development of database of calcaneal measurements in various populations is recommended.

### The study was performed in:

1. Tribuvan University Teaching Hospital, Department of Anatomy, Maharajgunj, Kathmandu, Nepal
2. Chitwan Medical College, Bharatpur-10, Chitwan, Nepal
3. Birat Medical College and Teaching Hospital, Tankisinwari, Biratnagar, Nepal

### Acknowledgement

We would like to thank the Department of Anatomy of Birat Medical College, Tribuvan University

Teaching Hospital (Kathmandu, Maharajgunj) and Chitwan Medical College for providing bones to conduct this study. Also our sincere thanks go to the faculties of anatomy department of the mentioned institutes for their support and cooperation.

### DECLARATION OF INTEREST

The authors declare that there are no conflicts of interests.

### Licensing

This work is licensed under a Creative Commons Attribution 4.0 International (CC BY 4.0) License

### Sažetak

## VRSTE GORNJE ZGLOBNE POVRŠINE I MORFOMETRIJSKA ANALIZA PETNE KOSTI KOD NEPALACA

Dhakal Arun,<sup>1</sup> Adhikari Prashant,<sup>2</sup> Khan G. Anwer,<sup>3</sup> Gautam Aajeevan<sup>3</sup>

<sup>1</sup> Department of Anatomy, Birat Medical College and Teaching Hospital, Biratnagar, Nepal

<sup>2</sup> Department of Orthopaedics, Grande International Hospital, Kathmandu, Nepal

<sup>3</sup> Department of Anatomy, Chitwan Medical College, Bharatpur, Nepal

**Uvod:** Tri najbitnije zglobne površine u gornjem delu kalkaneusa su prednja, srednja i zadnja artikularna površina. Izgled zadnje talarne površine i zadnje strane kalkaneusa je slična. Međutim, postoje razlike kada se posmatra zglobna površina kalkaneusa koja je predviđena da se zglobljava sa glavom talusa. Postoje četiri tipa kalkaneusa sa različitim talarnim površinama koja se navode u literaturi.

**Cilj:** Cilja ovog rada bio je da se opiše kalkaneus merenjem dimenzija i određivanjem varijacija talusne zglobne površine.

**Materijal i metode:** Ukupno 142 kalkaneusa (68 desnih, 74 levih) pacijenata kojima nije određivan pol su bili uključeni u studiju. Vernierov caliper i goniometrija su bili korišćeni.

**Rezultati:** Prva vrsta (Tip I) kalkaneusa (56,34%) pokazala se kao najčešća sa najvišom stopom prevalencije zajedno sa drugom vrstom (Tip II) petne kosti (42,25%), koja je drugom mestu po učestalosti. Treća po učestalosti vrsta kalkaneusa je tip IV (1,41%).

**Zaključak:** Tip I kalkaneusa je najčešći tip kod Nepalaca koji pokazuje sličnost sa rezultatima studija vršenim u špankoj, američkoj, afričkoj i različitim indijskim populacijama. Bolerov ugao desne i leve petne kosti bio je  $34.92^\circ \pm 8.09^\circ$  i  $35.4^\circ \pm 7.30^\circ$  respektivno. Preporučili bismo razvoj baze podataka za merenje parametara petne kosti u različitim populacijama.

**Ključne reči:** kalkaneus, talarna zglobna površina, Nepalci.

### REFERENCES

1. Standring S. Gray's Anatomy. 41st ed. Churchill Livingstone. 2016. p. 1424.
2. K. Anjaneyulu, Philips C, Tamang BK, Kumar A. Patterns of talar articulating facets in adult human calcanei from North-East India and their clinical correlation. Asian Journal of Medical Sciences. 2014; 5(4): 89-93 .
3. Ayoob A, De Maeseneer M, Shahabpour M, Van Roy P, Barbaix E, Qing S. The talocalcaneal unit: Pictorial review of anatomy and pathologic conditions on multi detector ct. JBR-BTR. 2010; 93(1): 20-7.

4. Uygur M., Atamaz F, Celik S, Pinar Y. The types of talar articular facets and morphometric measurements of the human calcaneus bone on Turkish race. Arch. Orthop. Trauma Surg. 2009; 129(7): 909-14.

5. Bunning PSC, Barnett CH. A comparison of adult and foetal talocalcaneal articulations. J Anat. 1965; 99(1): 71-6.

6. Dogan A, Albayrak M, Akman YE, Zorer G. The results of calcaneal lengthening osteotomy for the treatment of flexible pes planovalgus and evaluation of alignment of the foot. Acta Orthop Traumatol Turc. 2006; 40(5): 356-66.

7. Mosier KM, Asher M. Tarsal coalitions and peroneal spastic flatfoot. A review. J Bone Joint Surg Am. 1984; 66(7): 976-84.

8. Loucks C, Buckley R. Bohler's angle: correlation with outcome in displaced intra-articular calcaneal fractures. *J Orthop Trauma*. 1999; 13(8): 554-8.
9. Khoshall KI, Ibrahim AF, Al-Nakshabandi NA, Zamzam MM, Al-Boukai AA, Zamzami MM. Böhler's and Gissane's angles in the Saudi population. *Saudi Med J*. 2004; 25(12): 1967-70.
10. Daftary A, Haims AH, Baumgaertner MR. Fractures of the calcaneus: a review with emphasis on CT. *Radiographics*. 2005; 25(5): 1215-26.
11. El-Eishi H. Variations in the talar articular facets in Egyptian calcaneus. *Acta Anat. (Basel)*. 1974; 89(1): 134-8.
12. Drayer-Verhagen F. Arthritis of the subtalar joint associated with sustentaculum tali facet configuration. *J Anat*. 1993; 183(Pt3): 631-4.
13. Bunning PS, Barnett CH. Variations in the talocalcaneal articulations. *J. Anat*. 1963; 97: 643.
14. Gupta SC, Gupta CD, Arora AK. Pattern of talar articular facets in Indian calcanei. *J Anat*. 1977; 124(3): 651-5.
15. Forriol Campos F, Gomez Pellico L. Talar articular facets (Facies articulares talaris) in human calcanei. *Acta Anat*. 1989; 134(2): 124-7.
16. Bruckner J. Variations in the human subtalar joint. *J Orthop Sports Phys Ther*. 1987; 8(10): 489-94.
17. Norkin CC, Levangie PK. Joint structure and function: A comprehensive analysis. Philadelphia: F.A. Davis. 1983.
18. Smith RW. Computerized sectional imaging: computed tomography and magnetic resonance imaging of the foot and ankle. In *Disorders of the Foot and Ankle: Medical and Surgical Management* E H Wickland Jr; Philadelphia: W. B. Saunders 1991: 155-205.
19. Chavan SK, Satpute ST, Wabale RN. Pattern of talar articular facet of human calcaneum bone. *IOSR-JDMS*. 2014; 13(8): 16-8.
20. Rosenberg Z, Feldman F, Singson RD. Intra-articular calcaneal fractures: Computed tomographic analysis. *Skeletal Radiol*. 1987; 16(2): 105-13.
21. Kalenderer O, Agus H, Ak M, Ozluk S. Correlation of clinical and radiologic results of complete subtalar release in congenital clubfoot. *Acta Orthop Traumatol Turc*. 2003; 37(5): 368-73.
22. Su Y, Chen W, Zhang T, Wu X, Wu Z, Zhang Y. Bohler's angle's role in assessing the injury severity and functional outcome of internal fixation for displaced intra-articular calcaneal fractures: a retrospective study. *BMC Surg*. 2013; 13:40.

#### **Correspondence to/Autor za korespondenciju**

Dr Arun Dhakal,  
Email: arund@mail.ru  
Phone: +9779865105995