

Krstina S. Doklešćić,<sup>1</sup> Aleksandar R. Karamarković<sup>1,2</sup>

# ILEUM PERFORATION DUE TO ACCIDENTAL CHICKEN BONE INGESTION — A RARE CAUSE OF THE ACUTE ABDOMEN

Primljen/ Received: 08. 01. 2012. god.

Prihvaćen/Accepted: 28. 02. 2012. god.

**Summary:** Ingestion of foreign bodies is not an uncommon occurrence, but most of them will pass through the gastrointestinal tract without consequences. Complication such as perforation is rare.

We present a case of small bowel perforation secondary to the accidental ingestion of a chicken bone. The patient presented with abdominal pain, constipation and vomiting. Clinical examination confirmed generalized abdominal tenderness and rebound tenderness. Abdominal radiography showed multiple dilated loops of small bowel, and abdominal ultrasound (US) showed inflammatory changes on small bowel loops, with free fluid and fluid collection around intestinal loops. The patient underwent an emergency laparotomy. Intra operative findings revealed diffuse fibro purulent peritonitis with abscess between central small bowels loops. At about 60 cm from Bauchini valve we found a perforation of ileum at the anti-mesenteric site caused by a sharp chicken wishbone. The patient was treated with resection of the ileum segment (10 cm) and primary end-to-end anastomosis.

Even that intestinal perforation by a foreign body is rare, physicians should consider possibility of intestinal perforation by a foreign body in the differential diagnosis of acute abdomen in patients presenting with abdominal pain.

**Key words:** Small-bowel perforation, chicken wishbone, peritonitis.

## INTRODUCTION

The ingestion of sharp foreign bodies (FB), whether intentional or accidental, is not uncommon occur-

rence (1, 2, 3). The accidental ingestion of FB is more common among children, adolescents, the elderly, alcoholics or drug abusers, the mentally ill, and members of certain professions that hold small sharp objects in their mouths (carpenters, dressmakers and upholsterers), as well as among people that eat very quickly. Patients can not always recall ingesting a foreign body including chicken and fish bones and exploratory laparotomy remains final option in most cases (3). Foreign bodies, such as dentures, fish bones, chicken bones, and toothpicks, have been known to cause perforation of the gastrointestinal (GI) tract (1, 2,3).

Most foreign bodies will spontaneously pass through the gastrointestinal tract without consequence, but around 1% of cases will make complications including bowel perforation (1). The anatomical areas where FB impaction is most likely include narrow, angled or pouching zones, zones with adhesions or surgical anastomosis and zones containing a diverticules (1).

Clinical symptoms vary from abdominal pain with or without fever to focal or diffuse peritonitis or intra-abdominal abscess. Bowel perforation leads to acute abdomen and requires surgical treatment (2).

Here we present a case of small bowel perforation secondary to the accidental ingestion of a chicken bone. The diagnosis was made following resection of the affected bowel.

## CASE PRESENTATION

A 52-year-old woman was admitted to the Clinic for emergency surgery, Clinical Center of Serbia in Belgrade, with a 2-day history of abdominal pain, constipation and vomiting. Her past medical history included type 2 diabetes mellitus, arterial hypertension, and obesity (BMI=34). She had two previous operations: a

1 Clinic for Emergency Surgery, Clinical Center of Serbia, Belgrade, Serbia

2 School of Medicine, University of Belgrade, Serbia

Cesarean section 25 years ago and a cholecystectomy 5 years ago.

Physical observations revealed pyrexia of 38,3°C, sinus tachycardia, blood pressure 150/100 mmHg and normal oxygen saturation on room air. Clinical examination confirmed generalized abdominal tenderness and rebound tenderness. On listening to the abdomen with a stethoscope, no bowel sounds were heard, with lack of bowel movements and flatulence.

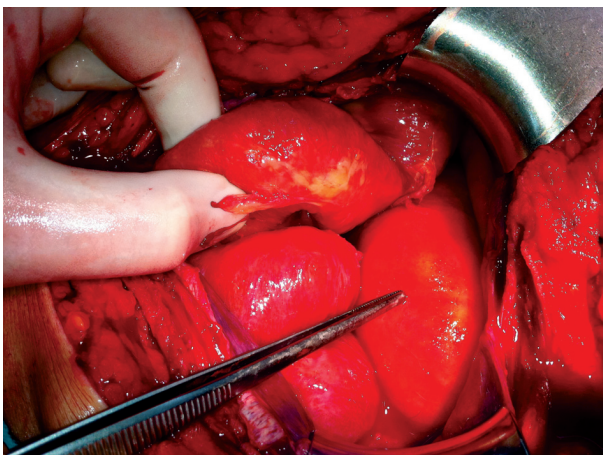
The emergency laboratory tests revealed the following: white blood cells (WBC) 20 x 10/liter; hemoglobin 112g /L; serum creatinine 128 mol/L; blood urea 6.6 mmol/L; blood glucose 12.5 mmol/L; Na 132 mmol/L; K 4.2 mmol/L; c-reactive protein 160 mg/L.

Plain abdominal radiography showed multiple dilated loops of small bowel, and no subdiaphragmal air. Abdominal ultrasound (US) showed inflammatory changes of small bowel loops, with a free fluid and fluid collection around intestinal loops and enlarged lymph nodes within the small bowel mesentery, close to the right ileocolic vessels.

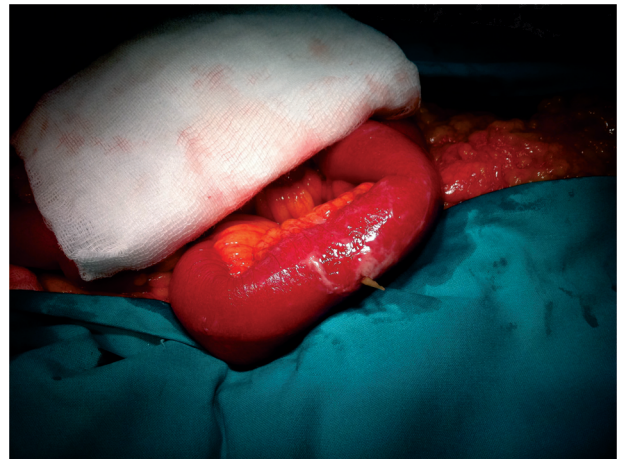
The patient underwent an emergency **laparotomy**.

Intra-operative findings revealed diffuse fibropurulent peritonitis with abscess between central small bowel loops. A single-band adhesion from this area of small bowel to the omentum was also noted. At about 60 cm from Bauchini valve we found a perforation of the ileum at the anti-mesenteric site (**Figure 1**).

The wall of that part of the ileum was succulent and perforated with a sharp chicken wishbone protruding (**Figure 2**). The patient was treated with resection of the ileum segment (10 cm) and primary end to end anastomosis. The peritoneal cavity was irrigated with 5 litres of warm normal saline and four closed suction drains were inserted and left in abdominal cavity. Abdominal fascia was closed with continuous, number 1 non-absorbable suture. The Redon drainage was placed in to the wound, and skin was sutured.



*Figure 1. Site of the ileum perforation*



*Figure 2. Chicken bone that perforated the bowel*

Postoperatively patient received **broad spectrum antibiotics** (Meropenem 1 gr, three times a day; Vancomycin 1gr, twice daily).

The hospital course was uneventful. The patient was feeling well, communicative, vital signs were stable. She began oral food intake on 4<sup>th</sup> postoperative day. The patient was discharged home on postoperative day 8<sup>th</sup>. During the 6 month follow-up period (including abdominal ultrasound after 3 and 6 month ) there were no complications.

Retrospectively, after operation the patient admitted that 3 days earlier she had rapidly eaten and swallowed several mouthfuls of chicken meat without chewing and accidentally ingested a chicken bone. Histopathological examination of the tissue reported a chicken bone that were embedded in the bowel — the sharp bone edges being responsible for the perforation and the bowel inflammation.

## DISCUSSION

Foreign body ingestion is the most commonly seen in children, alcoholics and people with mental health problems, like eating disorders (1). Foreign bodies accidentally ingested mostly pass through the gastrointestinal tract (GT) without any consequences (4). The most common objects are dentures, fish bones, chicken bones, toothpicks, and cocktail sticks (1).

The predominant types of ingested FB vary with geography and eating customs, with fish bones being more common in oriental countries and meat bones in western countries. The American Society for Gastrointestinal Endoscopy divided ingested FB into the following groups: (i) food bolus, generally of meat; (ii) blunt objects, such as coins; (iii) long objects, longer than 6–10 cm, such as toothpicks; (iv) sharp-pointed objects, such as fish bones or small bones; (v) disk batteries; and (vi) narcotic packets wrapped in plastic or latex (4).

Most foreign bodies will traverse the gastrointestinal tract uneventfully, however between 10 and 20% will fail to pass. Less than 1% of cases are reported to lead to complications (1). Elongated and/or sharp objects often impact at points of intestinal narrowing, with 83% of perforations occurring within the ileum (5).

**Small bowel perforations** by FBs are rarely diagnosed preoperatively because clinical symptoms are usually nonspecific and mimic other surgical conditions, such as: appendicitis, caecal diverticulitis, Inflammatory Bowel Disease (IBD) or Meckel diverticulitis (1, 5). Greater risk of perforation occurs in patients with previous bowel pathology, previous abdominal or gynecological operation, in alcoholic and psychiatric patients (6). The risk of perforation is related to the length and the sharpness of the object (7). Most perforations occur at the narrowing and angulations of the GI tract. The most common abdominal site of perforation is the distal ileum, caecum, and left colon (1, 3, 8).

**The clinical presentation** of complicated foreign body ingestion includes bowel obstruction, abscess formation, recurrent sepsis, bowel perforation with generalized peritonitis, perineum and scrotal abscess, enterovesical fistulas, intestinal obstructions, and gastrointestinal hemorrhage (1, 2, 9). The most common preoperative diagnosis was acute abdomen of uncertain origin (6). Our patient had a clinical presentation of acute abdomen with a suspicion to perforated appendicitis. We did not use CT because clinical signs and US indicated an emergency laparotomy. Patients with FB perforations in the stomach, duodenum, and large intestine are significantly more likely to be febrile, to have chronic symptoms, to have a normal total white blood cell count, and to be asymptomatic or present with an abdominal mass or abscess, compared to those with FB perforations in the jejunum and ileum (1). Patients that present with abdominal pain of unknown cause with muscle guarding should always be questioned about their recent food intake, including the possibility of foreign body ingestion.

Computer tomography (CT) scans of the abdomen have been reported to have a high sensitivity to identify intestinal perforation caused by alimentary foreign bodies (10). The CT identification of a FB, inflammation of the bowel loops, with a free fluid, abscess mass or

extra luminal collection of gas; in patients with clinical signs of peritonitis, mechanical bowel obstruction, or pneumoperitonem strongly suggests the diagnosis (10).

Nevertheless, definitive diagnosis was reached during laparotomy in more than 90% of the cases (1, 11). Rodríguez-Hermosa et al. in prospective study of 33 patients found abdominal contamination in all cases and diffuse peritonitis in 66,7% (12).

**Appropriated treatment** in cases of the small bowel perforations and peritonitis is surgery and antibiotic therapy. The surgery usually involves: simple suture of the defect, resection of the bowel with primary anastomosis or ileostomy/colostomy (1, 11, 12). In all cases of generalized peritonitis it is important to generously wash peritoneal cavity with warm normal saline and insert abdominal drains. Antibiotic therapy is essential in cases of intestinal perforation, and a wide variety of antibiotic regimens have been employed (13).

**The morbidity** attributed to intestinal perforation by FB is 24.2% and **the mortality** 6.5% (14). Reported complications include intra-abdominal abscess, perianal abscess, respiratory distress, endocarditis, intestinal fistula, Fournier's gangrene, digestive haemorrhage, prolonged ileus, wound infection, inflammatory mass, intestinal occlusion and diffuse peritonitis. The cause of death is usually multiple organ failure due to severe sepsis (14).

With respect to this case, during laparotomy we found diffuse fibro-purulent peritonitis and sharp-pointed chicken bone was found penetrating the inflamed portion of the distal ileum (Figure 2). We decided to do resection of the distal ileum with primary intestinal reconstruction, and the patient recovered uneventfully.

## CONCLUSION

Intestinal perforation by a foreign body is rare. When it happens it usually occurs in distal ileum, sigmoid colon or rectum. This case report highlights the importance to consider intestinal perforation by a foreign body as possible cause of acute abdomen in patients presenting with abdominal pain. Treatment consists of surgery and antibiotics. Appendicitis and acute diverticulitis should be considered in the differential diagnosis.

## Sažetak

## PERFORACIJA ILEUMA IZAZVANA SLUČAJNOM INGESTIJOM PILEĆE KOSTI — REDAK UZROK AKUTNOG ABDOMENA

Krstina S. Doklešćić,<sup>1</sup> Aleksandar R. Karamarković<sup>1,2</sup>

1 — Klinika za urgentnu hirurgiju, Klinički centar Srbije Beograd, Srbija,

2 — Medicinski fakultet, Univerzitet u Beogradu, Srbija

Ingestija stranih tela nije neuobičajena pojava, ali većina njih će proći kroz gastrointestinalni trakt bez posledica. Komplikacija kao što je perforacija je retka.

Prikazan je slučaj perforacije tankog creva nakon slučajne ingestije pileće kosti. Pacijent je primljen zbog abdominalnog bola, konstipacije i povraćanja. Kliničkim pregledom je potvrđena generalizovana abdominalna osetljivost. Radiografija abdomena je pokazala brojne dilatacije crevnih vijuga, ultrazvučni pregled abdomena je pokazao inflamatorne promene na vijugama tankog creva i slobodnu tečnost u truhu. Pa-

cijentu je izvedena hitna laparatomija. Intraoperativni nalaz potvrdio je difuzni fibro-purulentni peritonitis sa abscesom između centralnih vijuga tankog creva. Na rastojanju od oko 60 cm od Bauchini valvule nađena je perforacija ileuma na anti-mezenteričnoj strani, uzrokovana pilećom koščicom. Izvedena je resekcija ileuma (reseciran segment dužine 10 cm) i termino-terminalna anastomoza.

Iako je stranim telom izazvana perforacija tankog creva retka, lekari bi trebali ovu mogućnost uzeti u obzir u diferencijalnoj dijagnozi akutnog abdomena.

### REFERENCES

- Goh BK, Chow PK, Quah HM, Ong HS, Eu KW, Ooi LL. Perforation of the gastrointestinal tract secondary to ingestion of foreign bodies. *World J Surg* 2006; 30: 372–377.
- Akhtar S, McElvanna N, Gardiner KR, Irwin ST. Bowel perforation caused by swallowed chicken bones -a case series. *Ulster Med J* 2007; 76(1): 37–38.
- Bhatia R, Deane AJ, Landham P, Schulte KM. An unusual case of bowel perforation due to fish fin ingestion. *Int J Clin Pract* 2006; 60: 229–231.
- American Society for Gastrointestinal Endoscopy. Guideline for the management of ingested foreign bodies. *Gastrointest Endosc* 1995; 42: 622–5.
- Waseem A, Madina K. Intestinal perforation due to an ingested foreign body. *JCPSP* 2007; 17(4): 234–235.
- Ozel H, Topaloglu S, Yüksel BC, Aysar FM, Yildiz Y, Hengirmen S. Jejunal perforation in mentally retarded patient due to an ingested chicken bone. *Hepatogastroenterology* 2003; 50(Suppl 2): 137–139.
- Sarliève P, Delabrousse E, Michalakis D, Robert A, Guichard G, Kastler B. Multidetector CT diagnosis of jejunal perforation by a chicken bone. *JBR-BTR* 2004; 87: 294–295.
- Rasheed AA, Deshpande V, Slanetz PJ. Colonic Perforation by Ingested Chicken Bone. *AJR* 2001; 176:152.
- Moreira CA, Wongpakdee S, Gennaro AR. A Foreign Body (Chicken Bone) in the Rectum Causing Extensive Perirectal and Scrotal Abscess: Report of a Case. *Dis Colon Rectum* 1975; 18(5): 407–409.
- Coulier B., Tancredi M.H., Ramboux A. Spiral CT and multidetector-row CT diagnosis of perforation of the small intestine caused by ingested foreign bodies. *Eur Radiol* 2004; 14: 1918–1925.
- Pinero Madrona A, Fernández Hernández JA, Carrasco Prats M, Riquelme Riquelme J, Parrila Paricio P. Intestinal perforation by foreign bodies. *Eur J Surg* 2000; 166(4): 307–9.
- Rodríguez-Hermosa JI, Codina-Cazador A, Sirvent JM, Martín A, Gironés J, Garsot E. Surgically treated perforations of the gastrointestinal tract caused by ingested foreign bodies. *Colorectal Disease* 2008; 10(7): 701–707.
- Rodríguez-Hermosa JI, Farre's R, Codina A, Olivet F, Pont J, Girone's J, Roig J, Blanco J. Intestinal perforations caused by foreign bodies. *Cir Esp* 2001; 69: 504–6.
- Goh BK, Tan YM, Lin SE, Chow PK, Cheah FK, Ooi LL, Wong WK. CT in the preoperative diagnosis of fish bone perforation of the gastrointestinal tract. *AJR Am J Roentgenol* 2006; 187: 710–4.

Correspondence to/Adresa za korespondenciju  
Mr sci med dr Krstina Doklešćić  
Clinic for Emergency Surgery,  
Clinical Center of Serbia, Belgrade, Serbia  
Email: krstinadoklešćić@gmail.com