

## MISTAKES IN THE DIAGNOSIS AND TREATMENT OF PRIMARY ANGLE-CLOSURE GLAUCOMA: CASE REPORT

Maric Vesna,<sup>1</sup> Markovic Vujica,<sup>1,2</sup> Bozic Marija,<sup>1,2</sup> Marjanovic Ivan<sup>1,2</sup>

<sup>1</sup> Clinic for Eye Diseases, Clinical Center of Serbia, Belgrade, Serbia

<sup>2</sup> University of Belgrade, School of Medicine, Belgrade, Serbia

Primljen/Received 28. 02. 2016. god.

Prihvaćen/Accepted 04. 04. 2016. god.

**Abstract:** Primary angle-closure glaucoma (PACG) is a leading cause of blindness globally. It is a condition that is responsible for nearly half of patients who have a bilateral blindness caused by glaucoma. PACG is highly prevalent in Asian countries, as compared with Primary open-angle glaucoma (POAG), which is reported as the predominant disease among Whites, but prevalence of PACG in Europe has been underestimated previously. Early detection by effective screening and appropriate prophylaxis and treatment may prevent blindness from angle-closure glaucoma. The purpose of this study was to present through the cases of 3 patients with PACG the importance of each phase of glaucoma: diagnosis, treatment and follow-up.

**Key words:** Primary angle-closure glaucoma; blindness; YAG laser iridotomy; prophylaxis; risk factors.


### INTRODUCTION

There are considerable differences in the prevalence of angle closure among ethnic groups. Primary angle-closure glaucoma (PACG) is highly prevalent in Asian countries, compared with Primary open-angle glaucoma (POAG), which is reported predominant disease among Whites (1, 2). The prevalence of PACG in Europe is 0.1 % (3). However, the Egna –Neumarkt Glaucoma Study stated that the burden of PACG in Europe has been underestimated previously (4). PACG is estimated to affect 26% of people with glaucoma worldwide and is responsible for almost half the number of bilateral blindness caused by glaucoma (5). It is estimated that 21 million people worldwide will have angle-closure glaucoma in 2020 (6). The proportion of blindness caused by PACG is greater than caused by open angle glaucoma, two to five times more, because of the greater estimated morbidity of this disease (6, 7). Quigley et al. estimated that the number of pe-

ople with bilateral blindness from PACG will be 5.3 million worldwide by 2020 (6). Early detection by effective screening and appropriate prophylaxis and treatment may prevent blindness from angle-closure glaucoma. The purpose of this study was to present through the cases of 3 patients with PACG the importance of each phase of glaucoma: diagnosis, treatment and follow-up.

### CASE REPORT 1

A 61-year-old women, from Vojvodina, a psychiatrist by profession, presented with pain in her left eye and left half of the head and she went to ophthalmologist in her town. She also presented blurring of vision and she was referred to the Clinic for Eye Diseases, Clinical Center in Serbia as an emergency case. In recounting her previous medical history, she complained of frequent headaches, always in one half of the head. However, the headaches “were frequent in the female line” and she did not attach great importance. She had regular medical check-ups every year as part of the institution where she works [visual activity (VA) on both eyes (BE), intraocular pressure (IOP), funduscopy] and review of glasses for near and distance in 2-2.5 years. Family history of glaucoma was positive, grandmother had glaucoma. On the examination at the Clinic for Eye Diseases, the best corrected visual activities (BCVA) were 1.0 in the right eye (RE) and 0.7 in the left eye (LE) respectively, with +2.50 diopter sphere in BE. The IOP was 12 mmHg in RE and 50 mmHg in LE measured with Goldmann aplanation tonometry (GAT). The biomicroscopy showed shallow anterior chambers in BE and in LE moderate corneal edema, moderate conjunctival hyperemia and mid-dilated pupil. Gonioscopy revealed narrow angle in RE and a 360° closed angle in LE. Fundus examination using indirect ophthal-



**Figure 1.** Visual field result in LE was preserved central island of visual field in case 1

moscopy with Volk Superfield lens 90D showed cup to disc ration in RE 0.4 and in LE 1.0. Beside complete ophthalmic examination we did complete diagnostic observation included a visual field test using the Threshold C 24-2 Swedish Interactive Testing Algorithm (SITA) standard program with Humphrey visual field analyzer II (Carl Zeiss, Germany) and scanning laser ophthalmoscopy-Heidelberg retinal tomography (HRT II, Heidelberg Engineering, GmbH, Dossenheim, Germany, version 2.02). Visual field result in RE was normal and in LE was preserved central island of visual field (Figure 1). Central corneal thickness (CCT) values were measured by ultrasonic pachymeter (Alcon laboratories, OcuScan®RxP Ophthalmic Ultrasound system, Fort Worth TX) by trained ophthalmic technicians and were 587  $\mu\text{m}$  in RE and 616  $\mu\text{m}$  in LE. During hospitalization a laser peripheral iridotomy (LPI) performed on LE and filtration surgery on RE. On first post-operative day IOP was 12 mmHg in RE and 10 mmHg in LE and BCVA was 1.0 in RE and 0.9 in LE.

## CASE REPORT 2

A 37-year-old women, from south of Serbia, medical doctor by profession, presented with pain in her right eye and right half of the head and blurring of vision in RE and she went to ophthalmologist in her town. The local hospital diagnosis was Iridocyclitis serosa on RE and she was treated with topical corticosteroids, non-steroidal anti-inflammatory drugs, antibiot-

ics, acyclovir, anti-glaucoma medications (timolol, dorzolamide, brimonidine and latanoprost) and oral acetazolamide. IOP in RE in that period was 26-40 mmHg. She had no family history of eye disorders. After one month, she was referred to the Clinic for Eye Diseases, Clinical Center in Serbia as an emergency case. On examination at the Clinic for Eye Diseases, the BCVA was 0.4 in RE and 1.0 in LE, respectively. She had a refractive error of 1.0 Dioptre spherical equivalent hyperopia in each eye. IOP was 44 mm Hg right and 16 mm Hg left. The biomicroscopy showed typical presentation of acute angle closure glaucoma, including edematous cornea, shallow anterior chambre, fixed dilated pupil and glaucomatous flecks of lens in RE and shallow anterior chambre in LE. Gonioscopy revealed a 360° closed angle in RE and narrow angle in LE. Fundus examination was normal; the optic nerve head cup-to-disc ratios of 0.3 BE. We also did a visual field test using the Threshold C 24-2 Swedish Interactive Testing Algorithm (SITA) standard program with Humphrey visual field analyzer II (Carl Zeiss, Germany) and scanning laser ophthalmoscopy-Heidelberg retinal tomography (HRT II, Heidelberg Engineering, GmbH, Dossenheim, Germany, version 2.02). Pachymetry measurements indicated that the CCT was 562  $\mu\text{m}$  in RE and 572  $\mu\text{m}$  in LE. The patient underwent placement of LPI on BE. Despite maximal medical therapy and LPI, her IOP still were very high in RE. Trabeculectomy was performed on patient's right eye. The IOP postoperatively was 14 mmHg in RE and 16 mmHg in LE and BCVA was 1.0 BE.

## CASE REPORT 3

A 65-year-old women, from Belgrade, trader by profession, presented with pain in her left eye and blurring of vision and she was referred to the Clinic for Eye Diseases, Clinical Center in Serbia as an emergency case. In her previous medical history, she recounted that 7-8 years ago she had increased IOP in RE. At that time, she went to one private ophthalmology clinic where, she reported that they treated her with drops during one day and she underwent LPI on BE and ophthalmologists in that clinic told her that "she is cured glaucoma and after 2 days follow-up, other ophthalmic follow-up are not required and any further therapy". Her family history was positive, mother and grandfather had glaucoma. On the examination at the Clinic for Eye Diseases, the BCVA was 0.1 RE and 1.0 in LE, respectively, with +1.00 diopter sphere in RE and +0.75 diopter sphere in LE. IOP measured with GAT was 54 mmHg in RE and 13 mmHg in LE. On slit lamp examination conjunctiva showed hyperemia with fixed dilated pupil, subatrophy iris and peripheral iridotomy on 8.30

hours in RE (Figure 2) and shallow anterior chambers in BE (Figure 3) and peripheral iridotomy on 2.30 hours in LE (Figure 4). Gonioscopy revealed a 360° closed angle in RE and her Shaffer angle-closure grades were 2 in LE. Funduscopy revealed cup to disc ratio of approximately 0.8 and haemorrhagia on 12 hours in

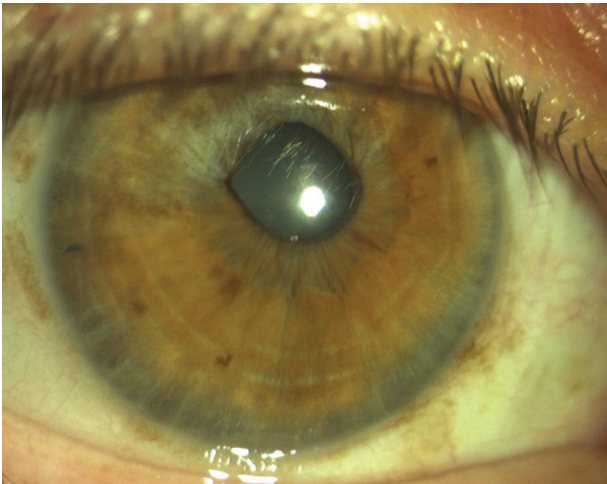


Figure 2. Fixed dilated pupil, subatrophy iris and peripheral iridotomy on 8.30 hours in RE in case 3

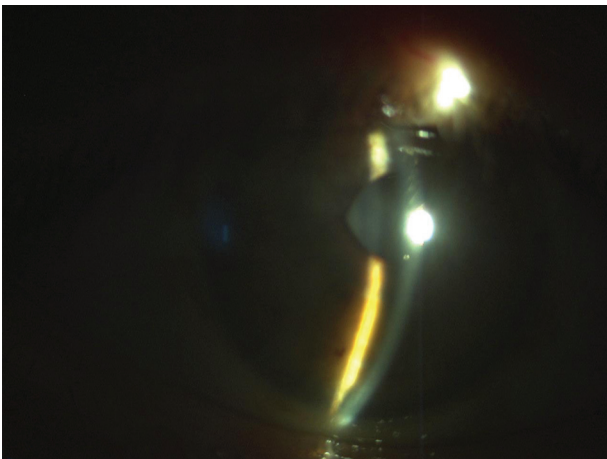


Figure 3. Shallow anterior chamber in case 3

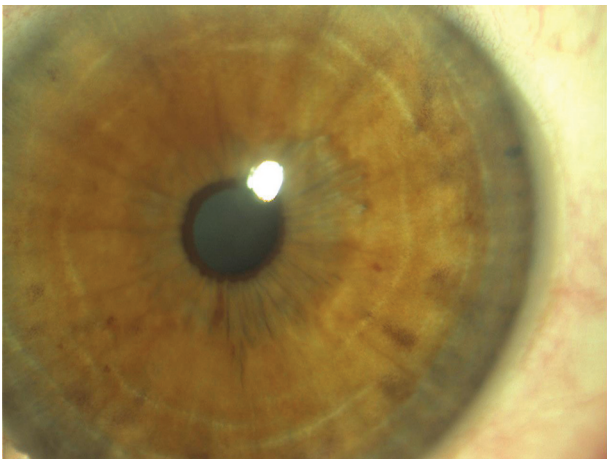


Figure 4. Peripheral iridotomy on 2.30 hours in LE in case 3

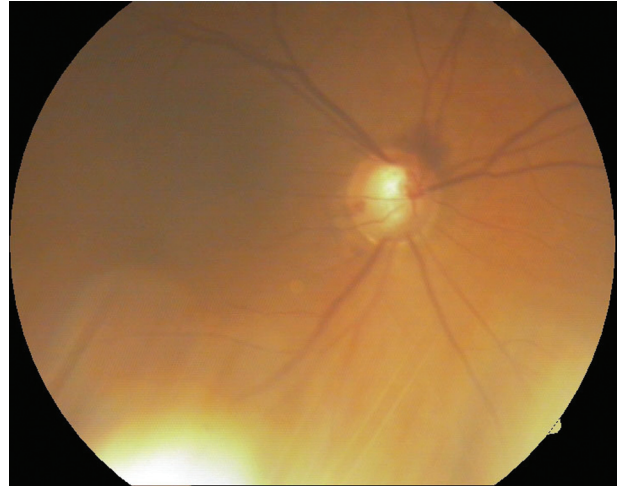


Figure 5. Foto fundus revealed cup to disc ratio of approximately 0.8 and haemorrhagia on 12 hours in RE in case 3




Figure 6. Visual field result on RE was preserved loss of the upper half of the visual field in case 3

RE (Figure 5) and 0.5 in LE. We also did scanning laser ophthalmoscopy-Heidelberg retinal tomography (HRT II, Heidelberg Engineering, GmbH, Dossenheim, Germany, version 2.02) and a visual field test using the Threshold C 24-2 Swedish Interactive Testing Algorithm (SITA) standard program with Humphrey visual field analyzer II (Carl Zeiss, Germany). Visual field result on RE was preserved loss of the upper half of the visual field (Figure 6). The pachymetry results were 590 μm in RE and 554 μm in LE. During hospitalization filtration surgery performed on RE. The BCVA postoperatively was 0.8 in RE and 1.0 in LE and IOP was 12 mmHg and 14 mmHg.



## DISCUSSION

PACG is preventable, yet is leading cause of blindness globally (8, 9). It is responsible for nearly half of patients who have a bilateral blindness caused by glaucoma (10). Because PACG appears to cause blindness more frequently than POAG, it is an important public health issue. In the study undertaken by Quigley et Broman (6), they predict that there will be 1.5 million people with PACG in Europe in 2020. Although POAG is seen more frequently than PACG in our population, PACG is more common than previously thought and we have common experience of it in our clinical practice. Outcome of PACG depends of stage of glaucoma. That is the reason why is necessary to recognize PACG on time, correct prophylaxis, treatment and follow-up. In our 3 cases, all of the patients presented with dramatic but characteristic symptoms of acute angle-glaucoma (AAG). There is, however, often significant overlap in the clinical presentation, as patients with underlying chronic disease may also present acutely during the course of the disease, and patients with acute angle closure can be subsequently go on to develop chronic angle-closure glaucoma.

It is important to know more about the pathophysiology and risk factors of PACG to improve prevention. Several risk factors have been identified for PACG, including female gender, older age, race, family history and ocular risk factors as shallow anterior chamber depth (ACD), hyperopia, short axial length, thick crystalline lens, steep corneal curvature (11, 12). New findings suggest iris volume and choroidal thickness to have a key role in the mechanisms of angle closure (13). In our 3 cases, the patients were female with hyperopic refractive errors. Women are known to be more susceptible to angle closure. They tend to have shallower anterior chamber depth and narrower angle than men, which is believed to predispose them to angle closure (14). It has been reported that PACG happens more often in hyperopic eyes (15), like in our patients. In our study, two of them were over 60 years old and were with positive family history of glaucoma. It is known that increasing age is also major risk factor for developing PACG, with the relative risk of acute angle-closure glaucoma in patients above the age of 60 being 9 times higher compared to younger patients (8). Family screening is vital in families with PACG as there is robust evidence for significant increased risk of angle closure in family members of an affected patient: first degree relatives may have a 1 in 4 risk of a primary angle-closure (PAC) disease requiring treatment (16).

No diagnosis of PACG without gonioscopy; gonioscopic examination remains the most important method of identifying signs of angle closure and should be

performed on all patients in whom angle closure is suspected to evaluate angle anatomy, appositional closure, and presence of peripheral anterior synechiae (PAS).

The guidelines of the European Glaucoma Society (3) state that if gonioscopic measurements indicate the anterior chamber angle (ACA) is in appositional contact between the iris and the posterior trabecular meshwork over at least 180°, the eye should be designated primary angle closure suspect (PACS). If PAS are present, PAC is diagnosed. Further, if glaucomatous optic neuropathy (GON) and a corresponding visual field defect are evident in eyes with PAC, the condition is termed PACG. Acute PACG, if left untreated, can cause devastating blindness in a very short time.

Ultrasound biomicroscopy and anterior segment optical coherence tomography (AS-OCT) contribute to a better understanding of the mechanisms of angle closure, helping the ophthalmologists in the diagnosis and treatment (13). With AC-OCT we can better evaluate anterior segment structural features - the angle, iris, and lens by obtaining an in vivo cross section of the entire anterior segment in a single image (17, 18).

The purpose of treatment is to preserve visual function and maintain quality life by preventing PACG or AAC from developing (12). Laser iridotomy is a definitive treatment to relieve pupillary block in PAC and PACG (19, 20). Iridotomy alone is not adequate as long-term therapy in eyes with PAC or PACG, and patients almost always require additional medical or surgical treatments (19). When laser iridotomy fails to open the ACA, laser iridoplasty may be recommended as one of the options in treatment for angle-closure. Laser peripheral iridoplasty works by shrinking and pulling the peripheral iris tissue away from the trabecular meshwork. But laser peripheral iridoplasty is usually as an adjunct to laser peripheral iridotomy (9, 20). Filtering glaucoma surgery is treatment when laser procedures and topical medications fail and trabeculectomy is the usual procedure in Clinic for eye diseases. Some studies document that lens extraction significantly widens the ACA in eyes with narrow, occludable angles and in angle-closure glaucoma (21, 22, 23) but it is not commonly used interventions in Clinic for eye diseases. In the study undertaken by Tham et al. (21), they compared phacoemulsification versus fs20 trabeculectomy in medically uncontrolled chronic angle-closure glaucoma without cataract and concluded that both, phacoemulsification and trabeculectomy are effective in reducing IOP, as trabeculectomy is more effective than phacoemulsification in reducing dependence on glaucoma drugs, but is associated with more complications.

It is important to highlight that the other eyes of patients presenting with acute angle-closure glaucoma are at risk of developing a similar attack because of the

similar anatomical structure in both eyes. Previous studies documented that without treatment, the high proportion of contralateral eyes of patients with acute angle-closure glaucoma go on to sustain acute attacks or develop some form of angle-closure glaucoma (24), since approximately half of fellow eyes of acute angle-closure patients can develop acute attacks within 5 years (25). Medical regime as pilocarpine has been shown to be entirely protective against AAC (26). As such, peripheral iridotomy/or iridectomy to the fellow eye has been advocated as prophylaxis against the development of AAC in the long-term.

## CONCLUSION

PACG is an important cause of visual morbidity in our country and many parts of the world. Ophthalmologists should be alert to the potential risk of PACG and to identify those patients who are at risk of developing PACG and AAG or in whom it is present. Furthermore, in view of its insidious nature, greater efforts will need to be targeted at screening and early detection of this condition. PACG cases should be managed promptly according to an established protocol that should include medications, laser or surgical treatment. It is important to reverse or prevent angle closure by considering the application of laser iridotomy on the fellow eye as well because it is at high risk for a similar event. With careful follow-up and timely measured IOP and the performance of certain diagnostic procedures (visual

field testing, imaging technologies as HRT, OCT, GDx), disease progression can be halted.

## Conflict of Interest Statement

The authors declare that there are no conflicts of interest.

## Abbreviations

**PACG** — Primary angle-closure glaucoma  
**POAG** — Primary open-angle glaucoma  
**VA** — visual activity  
**BE** — both eyes  
**IOP** — intraocular pressure  
**BCVA** — the best corrected visual activity  
**RE** — right eye  
**LE** — left eye  
**GAT** — Goldmann aplanation tonometry  
**HRT** — Heidelberg retinal tomography  
**CCT** — central corneal thickness  
**LPI** — laser peripheral iridotomy  
**AAG** — acute angle-glaucoma  
**ACD** — anterior chamber depth  
**PAC** — primary angle-closure  
**PAS** — peripheral anterior synechia  
**ACA** — anterior chamber angle  
**PACS** — primary angle closure suspect  
**GON** — glaucomatous optic neuropathy  
**AS-OCT** — anterior segment-optical coherence tomography

## Sažetak

# GREŠKE U DIJAGNOZI I LEČENJU PRIMARNOG GLAUKOMA SA ZATVORENIM UGLOM: PRIKAZ SLUČAJA

Marić Vesna,<sup>1</sup> Marković Vujica,<sup>1,2</sup> Božić Marija,<sup>1,2</sup> Marjanović Ivan<sup>1,2</sup>

<sup>1</sup> Klinika za očne bolesti, Klinički Centar Srbije, Beograd, Srbija

<sup>2</sup> Medicinski Fakultet, Univerziteta u Beogradu, Beograd, Srbija

**Sažetak:** Primarni glaukom sa zatvorenim uglom je vodeći uzrok slepila u svetu. Odgovoran je za gotovo polovinu pacijenata sa obostranim slepilom koji imaju glaukom. Primarni glaukom sa zatvorenim uglom je visoko prevalentan u Azijskim zemljama u odnosu na primarni glaukom otvorenog ugla koje je zastupljeniji među belom rasom; međutim prevalencija primarnog glaukoma sa zatvorenim uglom u Evropi je potcenjena. Rano otkrivanje

sa odgovarajućom profilaksom i lečenjem mogu sprečiti pojavu slepila kao posledice angularnog glaukoma. Cilj ovog rada je da kroz prikaz slučaja 3 pacijentkinje sa primarnim glaukomom sa zatvorenim uglom naglasi značaj svake faze glaukoma: dijagnoze, lečenja i praćenja.

**Ključne reči:** Primarni glaukom sa zatvorenim uglom, slepilo, Yag laser iridotomija, profilaksa, faktori rizika.

## REFERENCES

1. He M, Foster PJ, Ge J et al. Prevalence and clinical characteristics of glaucoma in adult Chinese: a population-based study in Liwan District, Guangzhou. *Invest Ophthalmol Vis Sci.* 2006; 47(7): 2782–8.
2. Casson RJ, Newland HS, Muecke J, et al. Prevalence of glaucoma in rural Myanmar: the Meiktila Eye Study. *Br J Ophthalmol.* 2007; 91(6): 710–4.
3. European Glaucoma Society. Terminology and guidelines for glaucoma, 4<sup>th</sup> ed. Savona, Italy: Editrice DOGMA S.r.l.; 2014. p100–110.
4. Bonomi L, Marchini G, Marraffa M et al. Epidemiology of angle-closure glaucoma: prevalence, clinical types and association with peripheral anterior chamber depth in Egna-neu-markt glaucoma study. *Ophthalmology.* 2000; 107(5): 998–1003.
5. Sng CC, See JS, Ngo CS, et al. Changes in retinal nerve fibre layer, optic nerve head morphology, and visual field after acute primary angle closure. *Eye (Lond).* 2011; 25(5): 619–25.
6. Quigley HA, Broman AT. The number of people with glaucoma worldwide in 2010 and 2020. *Br J Ophthalmol.* 2006; 90(3): 262–7.
7. Quigley HA. Glaucoma. *Lancet.* 2011; 377(9774): 1367–77.
8. Foster PJ. The epidemiology of primary angle closure and associated glaucomatous optic neuropathy. *Semin Ophthalmol.* 2002; 17(2): 50–8.
9. Ng WS, Ang GS, Azuara-Blanco A. Laser peripheral iridoplasty for angle-closure. *Cochrane Database Syst Rev.* 2012; 2:CD006746.
10. Resnikoff S, Pascolini D, Etya'ale D, et al. Global data on visual impairment in the year 2002. *Bull World Health Organ.* 2004; 82(11): 844–51.
11. Barkana Y, Dekel I, Goldich Y, Morad Y, Avni I, Zadok D. Angle closure in Caucasians—a pilot, general ophthalmology clinic-based study. *J Glaucoma.* 2012; 21(5): 337–41.
12. Caprioli J, Gaasterland DE, Gross RL, Jampel H, Kolker AE, Lamping KA et al. Primary Angle-closure. Preferred Practice Patterns. San Francisco: American Academy of Ophthalmology, 2000.
13. Marchini G, Chemello F, Berzaghi D, Zampieri A. New findings in the diagnosis and treatment of primary angle-closure glaucoma. *Prog Brain Res.* 2015; 221: 191–212.
14. He M, Huang W, Zheng Y, Asbirk PH, Foster PJ. Anterior chamber depth in elderly Chinese. The Liwan Eye Study. *Ophthalmology.* 2008; 115(8): 1286–90.
15. Senthil S, Garudadri C, Khanna RC, Sannapaneni K. Angle closure in the Andhra Pradesh Eye Disease Study. *Ophthalmology.* 2010; 117(9): 1729–35.
16. Lackar Y, Bouassida W. Drug-induced acute angle closure glaucoma. *Curr Opin Ophthalmol.* 2007; 18(2): 129–33.
17. Moghimi S, Ramezani F, He M, Coleman AL, Lin SC. Comparison of Anterior Segment-Optical Coherence Tomography Parameters in Phacomorphic Angle Closure and Acute Angle Closure Eyes. *Invest Ophthalmol Vis Sci.* 2015; 56(13): 7611–7.
18. Lee JR, Sung KR, Han S. Comparison of anterior segment parameters between the acute primary angle closure eye and the fellow eye. *Invest Ophthalmol Vis Sci.* 2014; 55(6): 3646–50.
19. Huang P, Wu LL. Evaluation of the efficacy of laser peripheral iridoplasty in reversing the darkroom provocative test result in Chinese patients with primary angle closure status post laser iridotomy. *Int J Ophthalmol.* 2015; 8(3): 580–4.
20. Lee JR, Choi JY, Kim YD, Choi J. Laser peripheral iridotomy with iridoplasty in primary angle closure suspect: anterior chamber analysis by pentacam. *Korean J Ophthalmol.* 2011; 25(4): 252–6.
21. Tham CC, Kwong YY, Baig N, Leung DY, Li FC, Lam DS. Phacoemulsification versus trabeculectomy in medically uncontrolled chronic angle-closure glaucoma without cataract. *Ophthalmology.* 2013; 120(1): 62–7.
22. Moghimi S, Lin S. Role of phacoemulsification in angle closure glaucoma. *Eye Sci.* 2011; 26(3): 121–31.
23. Emanuel ME, Parrish RK 2nd, Gedde SJ. Evidence-based management of primary angle closure glaucoma. *Curr Opin Ophthalmol.* 2014; 25(2): 89–92.
24. Ang LP, Ang LP. Current understanding of the treatment and outcome of acute primary angle-closure glaucoma: an Asian perspective. *Ann Acad Med Singapore.* 2008; 37(3): 210–5.

### Correspondence to / Autor za korespondenciju

Vesna Maric

Clinic for Eye Diseases, Clinical Center of Serbia

Pasterova 2, 11000 Belgrade, Serbia

Telephone: +381112688997 Fax: +381112688164

vesbabic@sezampro.rs