

ECTOPIC PANCREATIC TISSUE IN THE STOMACH: CASE REPORT

Lukić Dejan,^{1,2} Tatić Milanka,^{1,2} Radovanović Zoran,^{1,2} Ranisavljević Milan,^{1,2}
Kresoja Milana,¹ Đurić Mladen¹

¹ Department of Surgical Oncology, Oncology Institute of Vojvodina, Sremska Kamenica, Serbia

² University of Novi Sad, Faculty of Medicine, Novi Sad, Serbia

Primljen/Received 18. 01. 2017. god.

Prihvaćen/Accepted 20. 02. 2017. god.

Abstract: Introduction: Ectopic pancreas is a rare developmental anomaly. It is a presence of pancreatic tissue without anatomic or vascular continuity with the normally developed pancreas. The most common heterotopic site is the stomach commonly involving antrum and prepyloric region on the greater curvature or posterior wall. Ectopic pancreas is diagnosed by endoscopic ultrasound, gastroscopy and biopsy, CT scan and MRI of the abdomen, a definitive diagnosis is verified by histopathological examination. Treatment is surgical.

Case report: A 56-year-old woman presented with epigastric pain, nausea and fatigue. Esophagogastroduodenoscopy showed submucosal mass in the prepyloric region, biopsy was performed. Histopathological findings described normal gastric mucosa. Endoscopic ultrasonography and CT of the abdomen showed submucosal tumor, 18 mm in diameter, located in the prepyloric region. Surgical treatment was indicated. Gastrotomy with total extraction of tumor was performed. Histopathology findings showed ectopic pancreatic tissue in the submucosal and muscular layer of the stomach. Postoperatively patient fully recovered, and in the 2 year follow-up did not develop any symptoms related to gastrointestinal tract.

Conclusion: Although presentation of ectopic pancreatic tissue in stomach is a very rare condition, it should be considered during gastrointestinal diagnostic in patients with nonspecific gastrointestinal symptomatology. In most of cases, for this patients, surgery is curative and definitive solution.

Key words: Ectopic pancreas, stomach, surgery, heterotopic pancreas.

INTRODUCTION

Ectopic pancreas (EP) is a rare congenital anomaly that involves the presence of pancreatic tissue outside the normal anatomical location (1). It is a rare de-

velopmental anomaly with a reported incidence of 0.55–14% at autopsy (2, 3, 4), in approximately one in every 500 upper gastrointestinal surgical specimens and in 0.6–13% of necropsies (5-9). It was the first described in 1727 by Schultz in an ileal diverticulum, and the first histological diagnostic confirmation was described by Klob (10, 11) in 1859. Ectopic pancreas in the stomach also known as myoepithelial hamartoma, heterotopic pancreas or aberrant pancreas, is described as presense of pancreatic tissue outside its normal anatomical location. It is the presence of pancreatic tissue without anatomic or vascular continuity with the normally developed pancreas. Although it is common to occur intra abdominally from anywhere along distal end of the oesophagus to the colon, it has been reported very rarely in extra abdominal sites such as mediastinal cysts, bronchi, lung, umbilicus and brain (12, 13, 14). Out of gastrointestinal lesions, the commonest area is the upper gastrointestinal tract i.e. stomach (30%), duodenum (25%) and jejunum (15%). At rare instances it can also occur in association with hepatobiliary organs such as liver, gallbladder, common bile duct, cystic duct (2, 15). Heterotopic pancreas is usually found incidentally and is generally asymptomatic. However it may become symptomatic when complicated by inflammation, bleeding, obstruction or malignant transformation (16, 17). The most common heterotopic site is the stomach commonly involving antrum and prepyloric region on the greater curvature or posterior wall (18). Gastric EP is found in the submucosal layer of the gastric wall, usually localized prepyloric and pyloric. Symptoms can occur if there is inflammation, bleeding, gastric obstruction and malignant transformation. The most common symptoms are: nausea, vomiting, epigastric pain, melena (3).

Ectopic pancreas is diagnosed by endoscopic ultrasound, oesophagogastroduodenoscopy and biopsy, CT scan and MRI of the abdomen, a definitive diagno-

sis is verified by histopathological examination. Diagnosing of the EP in the stomach is very difficult due to the similarity with gastrointestinal stromal tumor (GIST), gastrointestinal autonomic nerve tumor (GANT), carcinoid, lymphoma and gastric cancer (4).

CASE REPORT

A 56 years old woman was admitted in hospital due to melena, severe abdominal pain and fatigue. She reported that symptoms involving black stools occurred in the last three days following the nausea, stabbing pain in the upper abdomen and left hypochondrium. She also complained about weakness, fatigue and sweating. Ten years ago patient had similar symptoms. Therefore, she underwent the oesophagoduodenogastroscopy and the submucosal tumor in the prepyloric region of the stomach was diagnosed, which did not act malignantly. Symptoms retreated, so the surgical treatment was not indicated, but during all these years patient was followed by the surgeon and gastroenterologist.

Clinical examination showed diffuse abdominal tenderness. Hematological and biochemical parame-

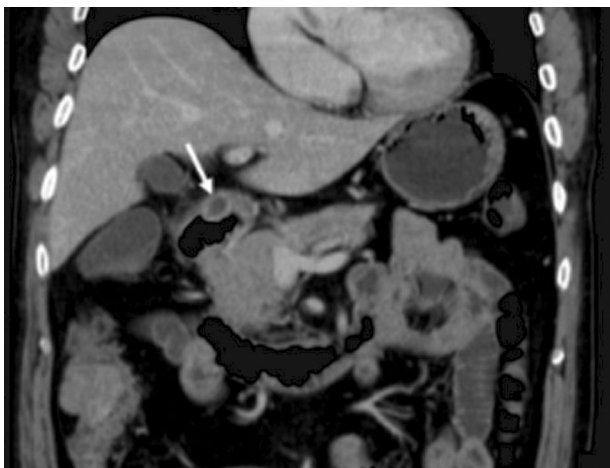


Figure 1. Submucosal mass of the stomach (CT)

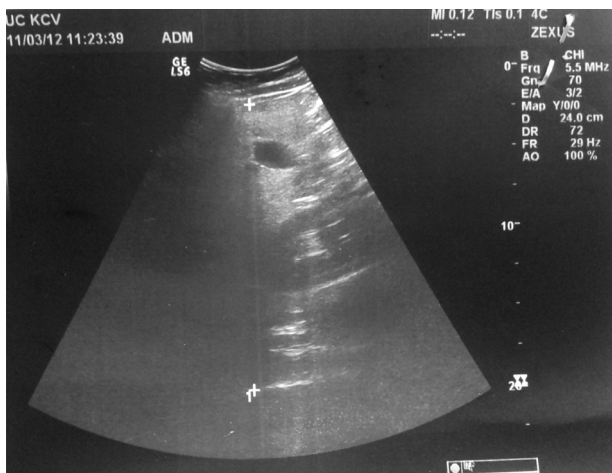


Figure 2. Hypoechoic mass in the antral region of the stomach

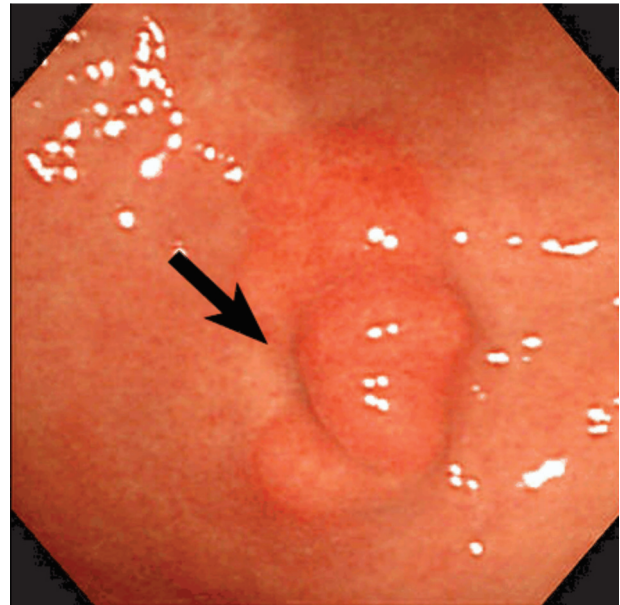


Figure 3. Gastroscopy, submucosal mass

ters were in the reference range, except mild sideropenic anemia. Native X-ray and ultrasound of the upper abdomen did not provide the significant data. The abdominal CT scan showed submucosal mass in the prepyloric region of the stomach (Figure 1).

Endoscopic ultrasound of the stomach discovered 18 mm submucosal gastric lesion in the prepyloric region of the stomach. The first assumption was GIST (Figure 2).

Oesophagoduodenogastroscopy confirmed the existence of submucosal tumor in the prepyloric region of the gastric mucosa (Figure 3). Biopsy was performed and specimen was sent to histopathology (HP) examination. HP findings had showed normal gastric mucosa.

Given the patient constant symptoms and results of CT, endoscopic ultrasonography and patohistological results, surgical treatment was indicated. After a usual preoperative preparation, surgery was performed in the general anesthesia. We used the upper medial laparotomy to access the stomach. Through palpation lesion was identified, about 5 cm from the pylorus, at the large curvature of the stomach, measuring about 20 mm, elastic consistency, clearly limited by the surrounding structures. Gastrotomy was done, mucosa above the tumor was intact. The tumor was completely removed and sent to HP analysis. The stomach was closed with continuous stitches in two layers. The postoperative course was uneventful, with no postoperative complications. The patient was discharged on the seventh postoperative day.

Histopathology findings showed the ectopic pancreatic tissue in the submucosal and muscular layer of the stomach. Ectopic pancreatic lobular structure, lobules, is located in the gastric submucosal layer. Lobules

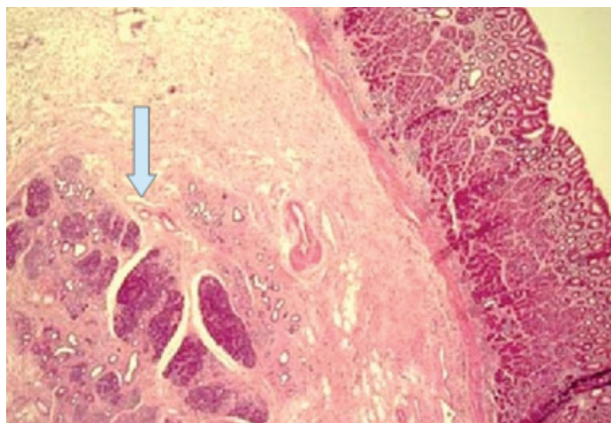


Figure 4. Pancreatic acini with ductal structures and islets of Langerhans

contain pancreatic acini with ductal structures, and islets of Langerhans, the mucosa above is intact (Figure 4).

DISCUSSION

The etiology of ectopic pancreas is unknown. It is believed that early, in fetal development, during the rotation of the digestive tube and connection of dorsal and ventral part of the pancreas, small parts remain separate and continue to develop at the atypical location (5). Ectopic pancreatic tissue is rare, with a reported incidence of 0.55 4% at autopsy (1, 7), in approximately one in every 500 upper gastrointestinal surgical specimens and in 0.6 3% of necropsies (8, 9). Gastric antrum is the commonest site for heterotopic pancreatic tissues in stomach which accounts about 85–95%, being more common along the greater curvature. Our patient had the lesion at the large curvature of stomach. The most common symptoms are: nausea, vomiting, epigastric pain, melena (3), which is consistent with our findings.

Diagnosing EP in the stomach is difficult. Although the EP of the stomach is rare, in cases with submucosal tumor in the gastrointestinal tract, it is necessary to consider the differential diagnosis of ectopic pancre-

as. Endoscopic examination has become useful adjunct in the evaluation of submucosal lesions. Despite the wide range of diagnostic possibilities, EP presents a diagnostic challenge. Although positive biopsy establishes the diagnosis, in most cases, biopsies are superficial and therefore non-diagnostic. Ultrasound of upper abdomen, CT, MRI and X-ray often provide poor results due to great similarities with GIST and GANT tumors, as well as carcinoid, lymphoma and gastric cancer. Definitive HP findings on operatively removed tumor provide helpful data for diagnosis (7, 9).

CONCLUSION

Although, presentation of ectopic pancreatic tissue in stomach is very rare condition, it should be considered during gastrointestinal diagnosing in patients with nonspecific gastrointestinal symptomatology. In the most cases, for these patients, surgery is curative and definitive solution.

Abbreviations

EP — Ectopic pancreas
CT — Computed Tomography
MRI — Magnetic resonance imaging
GIST — Gastrointestinal stromal tumor
GANT — Gastrointestinal autonomic nerve tumor
HP — Histopathology

All co-authors were actively involved in the collection and processing of data.

Conflict of interest

The authors declare that there is no conflict of interest.

Licensing

This work is licensed under a Creative Commons Attribution 4.0 International (CC BY 4.0) Licence

Sažetak

EKTOPIČNO TKIVO PANKREASA U ŽELUCU: PRIKAZ SLUČAJA

Lukić Dejan,^{1,2} Tatić Milanka,^{1,2} Radovanović Zoran,^{1,2} Ranisavljević Milan,^{1,2}
 Kresoja Milana,¹ Đurić Mladen¹

¹ Klinika za operativnu onkologiju, Institut za onkologiju Vojvodine, Sremska Kamenica, Srbija

² Medicinski fakultet Univerziteta u Novom Sadu, Novi Sad, Srbija

Uvod: Ektopični pankreas je retka razvojna anomalija koja podrazumeva prisustvo pankreasnog tkiva van uobičajene anatomske lokacije. Najčešće se nalazi na želucu antralno ili prepilorično na velikoj krivini zadnjeg zida. Ektopični pankreas se dijagnostikuje en-

doskopskom ultrasonografijom, gastroskopijom i biopsijom, CT-om i MR-om abdomena, a definitivnu potvrdu dijagnoze daje PH nalaz. Terapija je hirurška.

Prikaz slučaja: Žena stara 56 godina se žalila na bolove u želucu, mučninu i slabost. Ezofagogastroduo-

denoskopijom je uočena submukozna tumorska masa koja je bioptrirana. Patohistološki nalaz opisuje normalnu gastričnu mukozu. Endoskopskim ultrazvukom i CT-om abdomena, je uočen submukozni tumor prečnika 18 mm, lokalizovan u prepiloričnoj regiji želuca. Indikovana je i urađena operacija, gastrotomija i ekstrakcija tumora. Patohistološki nalaz je verifikovao ektopični pancreas u submukozi i muskularnom sloju želuca. Pacijentkinja se potpuno oporavila, tokom dvo-

godišnjeg praćenja nije imala simptoma vezanih za gastrointestinalni trakt.

Zaključak: Iako je ektopični pankreas na želucu retka pojava, u slučajevima dijagnostikovanja submukoznih tumora, potrebno je diferencijalno dijagnostički razmotriti i ektopični pankreas. Operativno lečenje je indikovano samo u slučajevima pojave simptoma.

Ključne reči: Ektopični pankreas, želudac, hirurģija, heterotopični pankreas.

REFERENCES

- Ormarsson OT, Gudmundsdottir I, Marvik R. Diagnosis and treatment of gastric heterotopic pancreas. *World J Surg.* 2006; 30(9): 1682–9.
- Christodoulidis G, Zacharoulis D, Barbanis S, Katsogridakis E, Hatzitheofilou K. Heterotopic pancreas in the stomach: a case report and literature review. *World J Gastroenterol.* 2007; 13(45): 6098–100.
- Chandan VS, Wang W. Pancreatic heterotopia in the gastric antrum. *Arch Pathol Lab Med.* 2004; 128(1): 111–2.
- Eisenberger CF, Gocht A, Knoefel WT, Busch CB, Peiper M, Kutup A, et al. Heterotopic pancreas-clinical presentation and pathology with review of the literature. *Hepatogastroenterology.* 2003; 51(57): 854–8.
- Pang LC. Pancreatic heterotopia: a reappraisal and clinicopathologic analysis of 32 cases. *South Med J.* 1988; 81(10): 1264–75.
- Matsushita M, Haji K, Okazaki K, Takakuwa H. Gastric aberrant pancreas: EUS analysis in comparison with the histology. *Gastrointest Endosc.* 1999; 49(4Pt1): 493–7.
- Low G, Panu A, Millo N, Leen E. Multimodality imaging of neoplastic and nonneoplastic solid lesions of the pancreas. *Radiographics.* 2011; 31(4): 993–1015. Shetty A, Paramesh AS, Dwivedi AJ, et al. Symptomatic ectopic pancreas. *Clinical Review.* 2002; 58: 203–207.
- Tanaka K, Tsunoda T, Eto T, Yamada M, Tajima Y, Shimogama H, et al. Diagnosis and management of heterotopic pancreas. *Int Surg.* 1993; 78(1): 32–5.
- Klob L. Pancreas accessorium. *Zeitschrift der Kaiserl. Konigl. Gesellschaft der Aerzte zu Wien.* 1859; 15:732.
- Caberwal D, Kogan SJ, Levitt SB. Ectopic pancreas presenting as an umbilical mass. *J Pediatr Surg.* 1977; 12(4): 593–9.
- Heller RS, Tsugu H, Nabeshima K, Madsen OD. Intracranial ectopic pancreatic tissue. *Islets.* 2010; 2(2): 65–71.
- Jaschke W, Aleksic M, Aleksic D. Heterotopic pancreatic tissue in a bronchogenic cyst-diagnosis and therapy. *Thorac Cardiovasc Surg.* 1982; 30(1): 58–60.
- Szabados S, Lenard L, Tornoczky T, Varady E, Verzar Z. Ectopic pancreas tissue appearing in a mediastinal cyst. *J Cardiothorac Surg.* 2012; 7:22.
- Hsia CY, Wu CW, Lui WY. Heterotopic pancreas: a difficult diagnosis. *J Clin Gastroenterol.* 1999; 28(2): 144–7.
- Emerson L, Layfield Lj, Rohr LR, Dayton MT. Adenocarcinoma arising in association with gastric heterotopic pancreas: a case report and review of the literature. *J Surg Oncol.* 2004; 87(1): 53–7.
- Papaziogas B, Koutelidakis I, Tsiaousis P, Panagioto-poulou K, Paraskevas G, Argiriadou H, et al. Carcinoma developing in ectopic pancreatic tissue in the stomach: a case report. *Cases J.* 2008; 1(1): 249.
- Galatioto C, Goletti O, Franceschi M, Buccianti P, Neri E, Amillota N, et al. Laparoendoscopic treatment of gastric ectopic pancreas. *Surg Laparosc Endosc Percutan Tech.* 1999; 9: 160–4.
- Christodoulidis G, Zacharoulis D, Barbanis S, Katsogridakis E, Hatzitheofilou K. Heterotopic pancreas in the stomach: a case report and literature review. *World J Gastroenterol.* 2007; 13(45): 6098–100.

Correspondence to / Autor za korespondenciju

Dejan Lukić

Oncology Institute of Vojvodina

Put dr Goldmana 4, Sremska Kamenica, Serbia

Phone: 021/480 5500

e-mail: dejan.lukic f.uns.ac.rs